

American Brachytherapy Society (ABS) consensus statement for sarcoma brachytherapy

Caroline L. Holloway^{1,*}, Thomas F. DeLaney², Kaled M. Alektiar³, Phillip M. Devlin⁴,
Desmond A. O'Farrell⁴, D. Jeffrey Demanes⁵

¹Department of Radiation Oncology, BC Cancer Agency, Vancouver Island Centre, Victoria, BC, Canada

²Department of Radiation Oncology, Massachusetts General Hospital, Harvard Medical School, Boston, MA

³Department of Radiation Oncology, Memorial Sloan-Kettering Cancer Center, New York, NY

⁴Department of Radiation Oncology, Dana-Farber Cancer Institute, Brigham and Women's Cancer Center, Harvard Medical School, Boston, MA

⁵Division of Brachytherapy, Department of Radiation Oncology, University of California, Los Angeles, CA

ABSTRACT

PURPOSE: To present recommendations for the use of brachytherapy (BT) in patients with soft tissue sarcoma (STS).

METHODS: A group of practitioners with expertise and experience in sarcoma BT formulated recommendations for BT in STS based on clinical experience and literature review.

RESULTS: The indications for adjuvant BT are discussed. There is no consensus on the use of BT alone or in combination with external beam radiation therapy (EBRT), but factors that influence the selection of this modality include tumor grade and size, prior surgeries, and tumor recurrence. Low-dose-rate, high-dose-rate, and pulsed-dose-rate radiation are all acceptable BT modalities to use for STS. Recommendations are made for patient selection, techniques, dose rates, and dosages. Outcome data and toxicity data are reviewed.

CONCLUSIONS: BT is a useful component of the treatment of STS. The advantages of BT are the targeted dose distribution, low integral dose, and short treatment times. Ultimately the clinician should select the modality or combination of modalities that are most familiar to the treatment team and suitable to the patient. © 2013 American Brachytherapy Society. Published by Elsevier Inc. All rights reserved.

Keywords:

Sarcoma; Brachytherapy; Consensus statement

Introduction

Soft tissue sarcomas (STSs) may occur anywhere in the body, including the extremities, trunk, and head and neck. There are many pathologic types and histologic grades with different natural histories. Surgery is the preferred primary treatment in most cases. Radiation and chemotherapy are important treatments that are typically supplemental to curative surgery. Alternatively, they may be applied with curative or palliative intent for unresectable lesions or inoperable patients. The primary goal of treatment is cure of the

disease with preservation of the structure and function of the affected body part or organ. Conservative surgery has generally replaced amputation as the treatment of choice for extremity sarcomas because it better accomplishes these dual objectives (1–3). The combination of wide local excision (WLE) with pathologically clear margins and radiation therapy is the preferred therapy in most patients. Selected cases with lesions less than 5 cm, particularly if superficial and low grade, may be considered for surgery alone (4, 5). The use of adjuvant external beam radiation therapy (EBRT) or brachytherapy (BT) to enhance local control (LC) in patients undergoing limb-sparing sarcoma resections in the extremity is supported by Level 1 evidence from randomized prospective clinical trials (6, 7).

Radiation therapy may be administered as preoperative external beam or postoperatively as either EBRT or BT. There are no controlled studies comparing EBRT with BT. Implant catheters are typically inserted at the time of surgical excision, which allows directed catheter placement

Received 26 September 2012; received in revised form 2 December 2012; accepted 31 December 2012.

There is no conflict of interest or financial disclosure for any of the authors.

* Corresponding author. Department of Radiation Oncology, BC Cancer Agency, Vancouver Island Centre, 2410 Lee Avenue, Victoria, BC V8R 6V5, Canada. Tel.: +1-250-519-5639; fax: +1-250-519-2018.

E-mail address: cholloway@bccancer.bc.ca (C.L. Holloway).

for disease coverage and protection of organs at risk (OARs). BT provides high radiation doses to the tumor bed and lower doses to tissues outside the implanted volume. If the target is localized to a region that can be encompassed with catheters, BT can be used as the sole therapy (8), although some data suggest improved outcome with a combination of BT and EBRT for patients with positive margins (9, 10). Source delivery can be done as low dose rate (LDR) as an inpatient or high dose rate (HDR) either as inpatient or outpatient depending on the medical and surgical care needs of the patient. In either case, BT courses are relatively short and convenient for patients. The limitations for BT in the treatment of sarcomas are the commonly large target volumes, restrictions in catheter placement because of bone or visceral organs, anatomic sites where good catheter geometry may be difficult to achieve (i.e., around the shoulder), and risk of radiation injury to nerves that are in direct contact with the BT catheters.

Methods and materials

A group of practitioners with expertise and experience in sarcoma BT were appointed by the American Brachytherapy Society (ABS) Board of Directors to provide a consensus statement for the use of BT in STS.

The previously published ABS guidelines were updated with a literature search, and the experts view on the state of the art was formulated. The evidence supporting BT as a component of the multidisciplinary management of sarcoma is described. Recommendations are made on radiation techniques and doses, and the expected tumor control and complication rates are provided. This consensus statement was submitted to the ABS Board of Directors for approval before publication.

Results

Patient selection

Ideally, patients should be evaluated by a multidisciplinary sarcoma team, which includes surgical, radiation and medical oncologists, radiologists, and pathologists with knowledge and experience in the management of sarcomas. Preoperative staging evaluations include careful examination of the affected body site for extent of disease and the functional status of the affected body structure followed by imaging of the tumor with MRI for pelvic, extremity, and truncal lesions and CT for abdominal and retroperitoneal lesions to determine the radiologic extent of disease. Preoperative imaging delineates the gross disease and associated tissue edema, and it may reveal invasion into surrounding structures. Identification of the relationship of the lesion to adjacent critical structures, such as bone, nerves, and blood vessels, can be used to plan the extent

and nature of the surgery. It is equally important to consider whether skin, soft tissue, bone, or vascular grafting will be required to repair the surgical defect.

Chest CT should be obtained to rule out lung metastasis, which is the most common site of distant spread; patients with low-grade T1 lesions can be adequately staged with a chest X-ray. CT of the abdomen and pelvis may be valuable for patients with extremity or truncal liposarcoma, epithelioid sarcoma, angiosarcoma, or leiomyosarcoma, which have a higher rate of extrapulmonary spread (11). PET/CT may be useful for histologies with a predilection for nodal metastases, including clear cell sarcoma, angiosarcoma, rhabdomyosarcoma, epithelioid sarcoma, and synovial sarcoma. MRI of the spine for patients with myxoid liposarcoma can also be considered (12). Detection of lung metastasis should prompt consideration of chemotherapy and possibly surgical resection depending on the number, location, size, and rapidity of progression (13–15). Metastectomy for non-pulmonary metastasis has also been reported (16–18).

Treatment modality

Surgery

Patients with small (<5 cm) superficial tumors or small deep tumors that can be resected with wide margins (>1 cm) or complete resection with the investing fascial barriers are candidates for surgery without radiation therapy (4, 5, 19).

Radiation

The indications for radiation therapy are those features that put the patient at risk for local recurrence after surgical resection. These factors include narrow or positive surgical margins, local recurrence after prior surgery, tumor size of >5 cm, lesions deep to or invading the superficial fascia, high grade, and younger than 50 years (20).

BT monotherapy as an adjuvant can be considered in patients with high-grade sarcomas of the extremity or superficial trunk if they have undergone complete surgical excision with negative margins (8). There is no consensus on whether BT should be combined with EBRT in the setting of positive margins or whether one modality is sufficient. Early data from Memorial Sloan-Kettering Cancer Center (MSKCC) showed that combined BT and EBRT had better LC for patients with positive margins (9), but in subsequent reports that difference was not observed (21). Factors that may influence the use of EBRT and BT in scenarios with positive margins include the tumor grade, prior surgeries, and tumor size (22). BT in combination with external beam is recommended for cases with recurrent disease who have not been previously irradiated (10, 23–25).

Location

The location of the primary sarcoma appears to impact the clinical outcome, and it may affect treatment planning

considerations for radiation therapy. Studies indicate that there may be differences in tumor control rates and morbidity between upper and lower extremity lesions as well as extremity vs. truncal lesions. The MSKCC group evaluated patients treated with either EBRT or BT and found that the upper extremity was associated with a greater rate of local recurrence compared with the lower extremity (26) independent of tumor size, depth, and margin status. Their group also noted the shoulder location as an independent prognostic factor for poor LC (8). Several BT series report increased toxicity in the lower limb compared with the upper limb (23, 27, 28). Sensitive locations such as the hands also have increased toxicity with radiation compared with surgery alone. In a retrospective review of 55 patients with STS of the hands, 26 had radiation with EBRT alone (21 patients) or combined with BT (5 patients). The complication rate was higher in the radiation cohort compared with the surgical cohort (19/26 vs. 3/29), and all 5 patients who underwent BT developed complications. The placement of BT catheters adjacent to finger joints seemed to be associated with complications (29). These studies indicate that for distal extremity (acral) lesions meticulous attention to treatment technique is warranted. The clinical circumstances, implant volume, target dose, timing of treatment, and other technical details of BT can have significant impact on outcome and must be carefully assessed before treatment.

The interstitial implant procedure

The most common method used for the treatment of STS is the placement of interstitial BT catheters at the time of surgical excision of the tumor where the surgical and radiation oncologists together define the tumor bed and target volume. The reason for intraoperative catheter placement is two-fold. First, the extent of the primary tumor is most apparent during surgery. The radiation target can be determined with both surgical and radiologic information. Second, the location of critical normal structures, such as bone, blood vessels, and nerves, affects the placement of the implant catheters, and their locations should be considered during the radiation treatment planning. Bones generally limit catheter placement so accommodation of bony anatomy is necessary. Penetration of arteries and veins and direct contact of BT catheters with nerves are to be avoided. Although peripheral nerves are generally tolerant to radiation, the very high doses of radiation adjacent to the sources may be injurious. Measures such as delineation of the course of the nerve in relationship to the implant sources or placement of spacers (e.g., gelfoam or temporary drains) between the catheters and the nerve are important procedural considerations. The placement of radio-opaque markers or clips is useful to demarcate the tumor bed target and the critical structures so they can be better identified during treatment planning.

Target volume

The target volume should consist of the surgical bed from which the tumor was excised plus a margin. The scar and drain sites are typically not targeted. There is no consensus on the size of the radiation treatment margin, and various prognostic factors, such as tumor size, resection quality, histology, may impact the judgment about the treatment volume. Other factors influencing the margin include natural anatomic boundaries, adjacent normal tissue dose constraints, potential seeding from prior procedures, and whether BT is used as monotherapy or in combination with EBRT (30). In general, at least 2 cm craniocaudally and 1–2 cm radially are recommended (30, 31).

Catheter placement

Interstitial implants are performed by passing hollow needles through the skin and soft tissue. The distance from the wound incision to the catheter entry point should be at least 1–2 cm. The needles are then replaced with one of the several kinds of BT catheters. The configuration of the implant must be individually tailored to the clinical circumstances. In general, the target is a volume of tissue rather than just a surface. Single-plane implants can be used if there is complete gross tumor removal (i.e., R0/R1 resection) and fascial plane barriers permit omission of deeper catheters or bone prevents additional catheter placement. Gross residual tumor must be encompassed by a volume implant to achieve optimal dosimetry. The number of BT catheters and the volume of the implant can vary widely depending on the size and location of the lesion. Catheters should be placed with the recommended craniocaudal and radial margins. Lesions of the hands and feet would be customized to accommodate smaller volumes and margins.

Catheters may be placed either parallel or perpendicular (Fig. 1) to the incision although mixtures with crossed ends can be useful. Parallel catheters usually are fewer and longer than perpendicular catheter arrays and may be most appropriate when the tumor bed contour follows the curvature of the extremity. Catheters and planes of catheters are placed at 1–1.5-cm intervals to ensure adequate dosimetry. Single-plane implants generally require closer spacing than multiplane volume implants to avoid scalloping of the prescription isodose. It is important to understand that wound closure can affect the catheter configuration through traction and bending as tissues are opposed and sutured together. The wound closure and catheter placement, therefore, must be done in concert to achieve satisfactory coverage of the clinical target volume (CTV).

Catheter stabilization is essential for quality treatment delivery. Catheters can be sutured directly into the surgical bed with absorbable sutures and are also anchored to the external skin surface with various devices such as fixing buttons. Another stabilization and spacing method is to thread the implant catheters through Jackson–Pratt drains

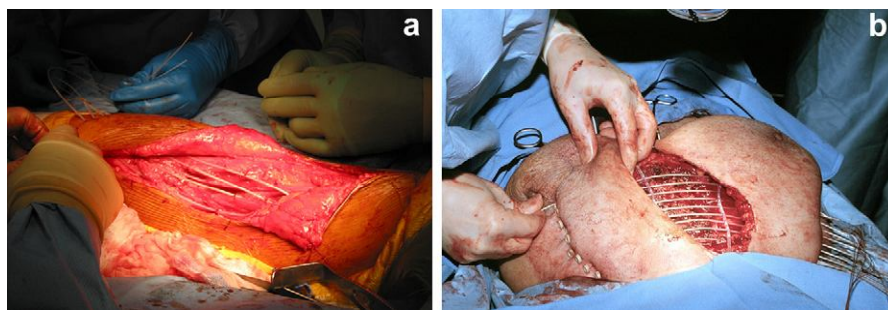


Fig. 1. Intraoperative placement of brachytherapy catheters demonstrating both (a) parallel and (b) perpendicular orientation of the catheters in relation to the wound. (b) Jackson–Pratt drains are used to immobilize the implant.

that can be placed within the wound and on the skin. These drains are oriented perpendicular to the catheters that pass through the drain holes to create a stable implant unit (Fig. 1) (32). Catheters may be open at one (single leader) or both (double leader) ends, if they run from skin to skin, or they may be blind ended and terminate within the wound. Stabilization of blind-ended tubes is more difficult than for skin-to-skin catheter arrangements. The Jackson–Pratt technique fixes the blind-ended tubes within the wound and helps prevent postoperative catheter displacements.

Tissue expanders can be used to protect normal structures from high exposure rates from the radiation sources. Gelfoam, drains, or inflatable (removable) materials can be placed between the catheters and critical structures to prevent normal tissue injury in the very high–dose region. The radiation oncologist must consider the effect of tissue expanders on target coverage during simulation and dosimetry calculations.

Catheter care and loading

Once the catheters are placed and the wound is closed, it is important to check the relationship of the catheters to the wound and ensure that there is sufficient space (~0.5 cm) between the catheter buttons and the skin to allow for postoperative swelling. The implant should be oriented so the catheters exit the skin in such a way as to easily insert the radiation source. Drains placed at the time of surgery should not be removed (Fig. 2) until after the BT is completed and the implant catheters are taken out to prevent inadvertent displacement of the catheters. This measure may also help decrease the risk of developing a seroma.

Simulation and dosimetry

BT catheters generally come with an internal leader that helps to prevent the catheters from stretching as they are pulled through the tissue during insertion. Before simulation, the internal leader of the catheters is removed and replaced with markers called “dummy ribbons,” which help to identify the potential source positions. The implant

catheters should be individually numbered for correct identification during source loading. The position of the catheter at the skin should also be marked for future reference during treatment delivery to ensure that the catheter depth has not changed between treatments.

CT simulation is the current standard for BT dosimetry of sarcomas. It allows for three-dimensional dosimetry of the implant. The radio-opaque markers or clips placed at the time of surgery help the physician contour the CTV. Presentation of axial isodose curves, dose–volume histogram (DVH) data, and virtual images facilitates understanding of the target doses and permits placement of dose constraints on normal tissue (Fig. 3). In BT, the CTV and planning treatment volumes are ideally congruous. The quality of the implant can be measured in terms of D_{90} (dose to 90% of the CTV), V_{100} (percent of the CTV that receives the 100% isodose), V_{150} (percent of the CTV that receives the 150% isodose), or similar measures. Normal tissue dose constraints are typically derived from the DVH data, which are represented as doses to various volumes, such as $D_{0.1cc}$, D_{1cc} , and D_{2cc} . An attempt should be made to limit the dose to the surgical incision to less than 100% isodose unless it is considered at high risk for tumor involvement. The dose to the skin

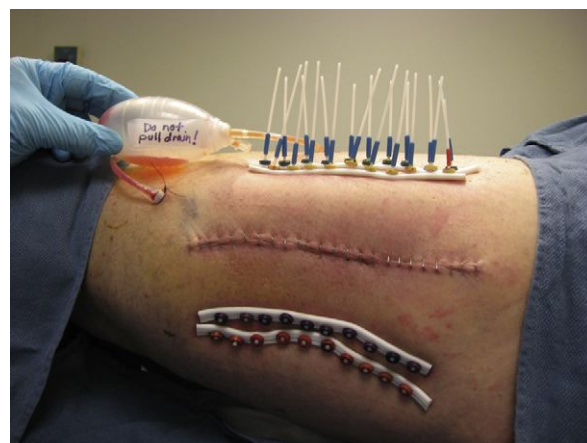


Fig. 2. Multiplane high-dose-rate radiation brachytherapy implant. The drain remains *in situ* until the implant is ready to be pulled at the completion of the brachytherapy course.

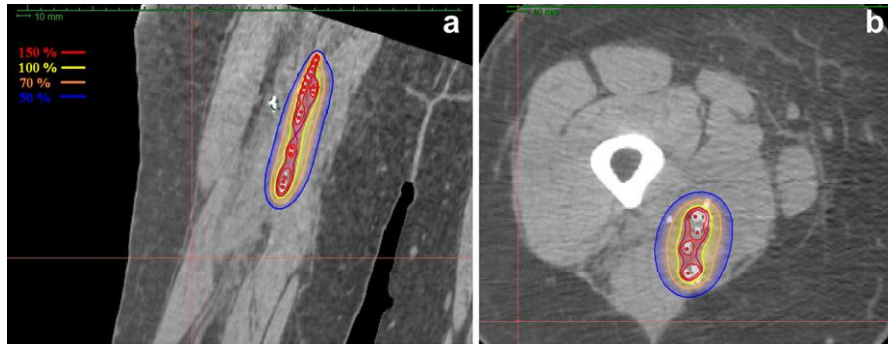


Fig. 3. Three-dimensional CT-based dosimetry of a brachytherapy implant as seen in (a) coronal and (b) axial planes. The 150–50% isodoses are demonstrated. (b) Surgical clips help to delineate the clinical target volume.

should be measured, and ideally should be no more than two-thirds of the prescribed dose. In addition, source loading should be no closer than 0.5 cm from the skin surface to minimize skin toxicity. There are limited data in the literature to equate DVH parameters with LC or toxicity outcomes.

Treatment delivery

Once dosimetry is completed, the prescription dose can be delivered to the CTV.

Treatment can be administered as an inpatient with LDR manual loaded sources (most commonly iridium-192 [^{192}Ir] seeds embedded in ribbons). Radiation safety precautions related to time of exposure, distance, and shielding are needed on the wards, where the patients are confined for the duration of the implant. Alternatively, HDR remote afterloading may be selected. It has the advantage of avoiding radiation exposure to personnel, and for many sarcomas, the treatment can be given as an outpatient. In LDR dosimetry, the median peripheral dose rate, defined as the lowest continuous isodose rate line that covers the CTV (usually ~ 0.45 Gy/h), is identified. This is generally 5 mm from the plane of the implant. The dosimetry for CT-based HDR is optimally volume based as described, or it can also be calculated at a point 5 mm from the catheters. Pulsed dose rate (PDR), a hybrid source delivery method that involves remote afterloading in short bursts at hourly doses at rates, is thought to be radiobiologically comparable to LDR. Regardless of the source delivery method, the patency, position, and integrity of the implant catheters should be verified daily during LDR treatment delivery and before each remote afterloading treatment.

It is recommended that the patient be clinically assessed for surgical complications before source delivery. Immediate postoperative complications, such as hemorrhage, seroma, wound breakdown, dehiscence, or infection, may delay loading of radiation and necessitate repeat treatment planning. Typically, 5 days is allowed to elapse for wound healing before treatment starts depending on the extent and location of the surgery and the relationship of the implant to the wound closure. ^{192}Ir source loading (LDR or HDR)

has been described in the literature between postoperative Day 2–4 (33) and Day 5–8 (7). MSKCC found decreased toxicity with loading Day 5 or more (34).

Catheter care and removal

The surgical wound and implant catheters should be kept as clean and dry as possible. This objective may be accomplished by the application of sterile dressing between cleansings. The patient should avoid showering, bathing, or wetting the implant catheters except during wound care. Antibiotic ointment may be applied sparingly at the catheter entrance and exit sites. Catheter removal should be in as clean a fashion as possible. In the removal of double leader implants, the catheters should be sterile prepared on the side that will be cut at the skin surface. The skin should then be depressed slightly so the catheter can be cut in a way to avoid pulling the external aspect of the catheter through the wound.

Treatment results according to dose rate: LDR, HDR, and PDR

Low dose rate

Dose rate is an important consideration in BT. Interstitial catheter BT for STS has used LDR iridium wires or seeds in ribbons that are loaded manually in the catheters. A randomized study (7) and a number of prospective and retrospective reports have evaluated LDR BT either as monotherapy or in combination with EBRT (9, 22, 35–43).

LC after LDR monotherapy is reported between 66% and 96% and LDR BT and EBRT between 78 and 100%. The complication rates are also comparable with reoperation rates of 10–12% for monotherapy and 2.3–13.8% for BT and EBRT (Table 1). Alekhteyar *et al.* (9) evaluated 105 patients who underwent WLE followed by LDR BT vs. LDR BT and EBRT. They did not find a significant difference in 2-year LC between the cohorts (90% vs. 82%) but a trend for improved LC in patients with positive margins who had BT and EBRT compared with BT alone (90% vs. 59%, $p = 0.08$). There was no difference in wound complication rate (26% vs. 38%). Laskar *et al.* (44)

Table 1
LC and complication rates of selected LDR and PDR BT series

First author	Year	FU (mo)	Modality	n	LC (%)	Complications > grade 2 (%)
Alekhteyar (9)	1996	22	LDR BT	87	82	16
			LDR BT + EB	18	90	27
Pisters (5)	1996	76	LDR BT	56	82	14
Chaudhary (43)	1998	40	LDR BT	33	75	1
			LDR BT + EB	118	71	
Delannes (38)	2000	54	LDR BT	58	89	17
Alektiar (8)	2002	61	LDR BT	202	84	12
Rosenblatt (39)	2003	36	LDR BT	9	87.5	16
			LDR BT + EB	21		
Andrews (22)	2004	69	EB	61	83	8
			LDR BT + EB	25	90	
Lazzaro (51)	2005	34	PDR BT	18	88	7
			PDR BT + EB	24	92	
Llacer (28)	2006	58	LDR BT	6	90	45
			LDR/PDR BT + EB	73		
Laskar (42)	2007	45	LDR/HDR BT	54	61	5 ^a
			LDR/HDR BT + EB	100	83	30 ^a
Mierzwa (41)	2007	39	LDR BT	24	79	4
			LDR BT + EB	19	100	21
Beltrami (40)	2008	75	LDR BT + EB	112	87	12.5
Muhic (52)	2008	41	PDR BT + EB	39	83	21

LC = local control; LDR = low dose rate; PDR = pulsed dose rate; BT = brachytherapy; FU = followup; EB = external beam radiation.

^a Wound fibrosis.

reported 50 pediatric patients who underwent WLE and then either BT or BT and EBRT. They found LC to be comparable (78% vs. 84%, $p = 0.89$).

Andrews *et al.* (22) reported on 86 patients treated with EBRT alone (61 patients) or in combination with BT (25 patients). The decision to use BT was based on a perceived risk of microscopically positive margins. There was no difference in 5-year overall survival (OS) (82% vs. 72%, $p = 0.93$) or LC (90% vs. 83%, $p = 0.15$). However, in univariate analysis of Stage III patients, the LC was improved if treated with EBRT and BT (100% vs. 62%, $p = 0.03$). Also high-grade lesions tended to have improved LC with EBRT and BT (100% vs. 74%, $p = 0.09$). No factors predicted for improved LC on multivariate analysis, possibly because of the small sample size. In a review by Laskar *et al.* (42), 155 patients (98 treated with LDR and 57 with HDR) had WLE of the primary tumor with BT alone (55 patients) or with EBRT (100 patients). In their cohort, the disease-free survival (DFS) and OS were superior in superficial tumors less than 5 cm. Dose greater than 60 Gy was found to favorably impact LC, DFS, and OS. They found fewer complications with BT monotherapy compared with BT and EBRT.

The justification for LDR BT for STS rests on these outcome reports and is supported by radiobiologic theory, which predicts for tumor control and normal tissue tolerance when sufficient and properly distributed radiation doses are applied. The limitations of LDR are radiation exposure to personnel, patient isolation for prolonged periods, limitations on nursing care, and potential for unrecognized catheter or source displacement.

High dose rate

HDR BT with remote afterloading has become increasingly prevalent (Table 2) because of improved radiation safety and better control of the dose distributions associated with a stepping source. There are several reports on HDR monotherapy (10, 24, 45–48). Itami *et al.* (24) reported on 25 patients (26 lesions) treated with 36 Gy in six fractions of HDR (a dose that would be predicted to control microscopic disease). Their overall 5-year local regional control was 78%. LC in patients with positive margins and previous surgical resections was only 43.8% compared with 93% for patients with negative margins and no previous resections. All local recurrences were outside the treated volume. They concluded that EBRT should be added for patients with previous surgery or positive margins as most of the recurrences would have fallen within a traditional EBRT volume. Koizumi *et al.* (47) reported on 16 lesions treated with HDR 40–50 Gy in 7–10 fractions over 4–7 days twice a day (BID) prescribed at 5 or 10 mm from the source. LC was 50%. Of the eight uncontrolled lesions, 63% had macroscopically positive resection margins that may explain the relatively low LC rate. Although not strictly comparable to results in adults, Nag *et al.* (48) reported 80% long-term LC in children treated with HDR monotherapy (36 Gy in 12 fractions) with 20% Grade 3–4 long-term complications.

Most of the reported HDR experience is with combined EBRT (10, 23, 25, 39, 46, 49, 50). Petera *et al.* (10) retrospectively reviewed 45 patients with primary or recurrent STS who either underwent HDR monotherapy (30–54 Gy) or HDR (15–30 Gy) and EBRT (40–50 Gy). The

Table 2
LC and complication rates of selected HDR BT series

First author	Year	FU (mo)	Modality	n	LC (%)	Complications	
						>Grade 2 (%)	Reoperation (%)
Koizumi (47)	1999	30	HDR BT	16	50	6	NR
Itami (24)	2010	50	HDR BT	26	78	11.5	7.7
Chun (25)	2001	31	HDR BT + EB	17	100	NR	6
Martinez-Monge (49)	2005	23	HDR BT + EB	25	23	28	NR
Aronowitz (50)	2006	34	HDR BT + EB	12	83	NR	25
Petera (10)	2010	38	HDR BT	11	55	4.4	2
			HDR BT + EB	34	85		
San Miguel (23)	2011	49	HDR BT + EB	60	77.4	28.3	10
Emory (46)	2012	11	HDR BT	37	92	NR	22
			HDR BT + EB	12	83	NR	33

LC = local control; HDR = high dose rate; BT = brachytherapy; FU = followup; NR = not reported; EB = external beam radiation.

use of EBRT was at the discretion of the treating oncologist. They reported 100% LC for primary tumors compared with 64% for recurrent tumors. LC was superior for extremity lesions compared with trunk tumors and HDR and EBRT compared with BT alone (odds ratio = 0.21; 95% confidence interval: 0.026, 0.651, $p = 0.013$). LC was also improved with doses greater than 65 Gy. A Japanese group reported their experience of HDR and EBRT. Their inclusion criteria were (1) high tumor grade, (2) low-grade tumor ≥ 10 cm, (3) recurrent tumor, (4) tumor abutting or invading critical structures, and (5) positive margins. They prescribed 2–3 Gy/fraction \times 6, BID combined with EBRT (36–60 Gy). After a median follow-up of 31 months, there was no local failure within the radiation field (25). San Miguel *et al.* (23) combined 45 Gy of EBRT with 16 or 24 Gy HDR BT depending on the margin status. LC at 9 years was reported as 77.4%. Positive margins had a 4.4-fold risk of local failure compared with close or negative margin ($p = 0.036$). They report 30% Grade 3–4 toxic events, with the majority related to wound healing. Despite this relatively high rate of toxicity, the reoperation rate was comparable to other series at 10%. Lower limb location and volume of the 150% isodose ($TV_{150} > 27$ mL) combined predicted for Grade 3 complications ($p = 0.003$).

There is no randomized comparison of HDR and LDR BT. Pohar *et al.* (27), however, published a historical control comparison in 37 patients treated between 1995 and 2004. Twenty-seven patients had LDR and 17 patients HDR (since 2001). The mean EBRT dose was approximately 50 Gy. The LDR dose was 15 Gy prescribed at 6-mm depth (0.42 Gy/h) based on the Paris system of loading. The mean HDR dose was 13 Gy (10.2–18 Gy) over three to four fractions BID. They noted an increase in toxicity in patients receiving >15 Gy HDR and adopted a standard HDR dose of 4.5 Gy \times 3 (13.5 Gy). LC was 90% with LDR and 94% for HDR. There was a trend of decreased occurrence of severe complications (Grade 3–4) in the HDR group (30% LDR vs. 6% HDR $p = 0.06$). Laskar *et al.* (44) retrospectively reviewed their pediatric data for patients who underwent WLE with BT

with or without EBRT. Both LDR and HDR were in their cohort. Of 50 patients, 30 had BT alone (LDR or HDR). They concluded that LC related to size of tumor and grade (better control for tumors <5 cm and low-grade tumors). LC for BT and EBRT was comparable to BT alone (78% vs. 84%, $p = 0.89$), and there was no difference in LC between LDR and HDR either as monotherapy or in combination with EBRT (77% vs. 92%, $p = 0.32$; 67% vs. 100%, $p = 0.17$).

We concluded, therefore, that HDR is also a valid approach to source loading for STS. The radiobiology of large fraction sizes and the potential for creative combinations of HDR BT with systemic therapy is yet to be explored. HDR has some functional and radiation safety advantages for pediatric patients.

Pulsed dose rate

There are a limited number of reports on the use of PDR BT in STS (28, 51, 52). The LC and toxicity appears consistent with LDR treatments with reported local regional control rates of 83–90% at 5 years, despite the large number of cases with positive margins (19–45.6%). In the study by Llacer *et al.* (28), LDR or PDR as monotherapy (45 Gy) or in combination with EBRT (20 Gy BT and 45 Gy EBRT) was used. All tumors involved the neurovascular structures (45.6% positive margins). The 5-year LC was 90%. Late complications related to lesion location in the lower limb, the number of catheters, and treatment thickness of 20 mm or more. They did not evaluate a difference between the two techniques. Muhic *et al.* (52) reported a reoperation rate of 10% for patients receiving 20 Gy PDR and 50 EBRT. This result is comparable to reports in the LDR literature. Therefore, PDR is also considered a suitable source loading method for STS.

Dose rate summary

All the described BT dose rate delivery systems, with their various advantages, are valid alternatives (Table 3). Studies are not available to separate outcome benefits for one dose rate over another. The extent of the disease, quality of the implant, case selection, and use of external

Table 3
Recommended BT prescription doses for primary STS treatment

Modality	EB (Gy)	BT (Gy)	Days	Comment
LDR BT		45–50	4–6	0.45–0.5 Gy/h
LDR BT + EB	45–50	15–25	2–3	0.45–0.5 Gy/h
HDR BT		30–54 ^a	4–7	2–4 Gy BID ^b
HDR BT + EB	45–50	12–20	2–3	2–4 Gy BID
PDR BT		45–50	2–3	0.45–0.5 Gy/h
PDR BT + EB	45–50	15–25	3–4	0.45–0.5 Gy/h

BT = brachytherapy; STS = soft tissue sarcoma; EB = external beam radiation; LDR = low dose rate; PDR = pulsed dose rate; HDR = high dose rate; BID = twice a day; Gy = gray.

^a HDR monotherapy included patients with positive margins or recurrent disease.

^b Several authors recommend 6-hour intervals for BID HDR BT (46, 47).

beam are equally and perhaps more important outcome variables.

Complications/safety

The impact of BT on acute and chronic complications is somewhat unclear because treatment is usually multimodal. Factors that influence the complication rates include tumor stage, disease location, the nature and extent of the resection, and previous or planned EBRT or chemotherapy. Wound complication rates range from 7% to 59% (10, 21, 23, 24, 27, 28, 38, 42, 51, 52). Delayed wound healing is the most common acute complication. The MSKCC randomized trial reported no significant difference in the wound complication rate as a consequence of BT (24% BT vs. 14% no BT; $p = 0.13$), but the rate of wound reoperation was significantly higher in the BT arm (10% vs. 0%; $p = 0.006$) (34). The rate of reoperation reported in the literature is 2.3–13.8% (23). Strategies to decrease wound healing complications include waiting for several days before source loading and the use of free flaps to decrease the wound tension (53, 54). The literature indicates that BT is safe when performed in association with free tissue transfer (55–58).

Wound complication rates after LDR BT are affected by various factors such as time to source loading more than 5 days (34) and good implant geometry (27), which are both associated with lower morbidity. The number of BT catheters or wires (>10) and treatment thickness >20 mm have also been reported to impact on vascular toxicity (28). Toxicity associated with HDR appears to be related to total radiation dose, total BT dose, HDR fraction size, and the volume encompassed by the 150% isodose line (23, 27, 50). Aronowitz *et al.* (50) have recommended that boost HDR BT be given at doses <15 Gy in three to four fractions (<4.5 Gy/fraction) given twice daily. Wound healing with HDR and LDR BT appears to be similar. A retrospective comparison of LDR and HDR BT and EBRT Grade 2–4 wound healing complications were 40% in the LDR cohort and 18% in the HDR cohort ($p = 0.14$), and there was a trend of decreased severe complications (Grade

3–4) in the HDR group (30% LDR vs. 6% HDR; $p = 0.06$) (27).

Other complications include chronic injury to bones and nerves. Bone fractures are reported in 0–4.5% of cases treated with BT (23). In the MSKCC randomized trial of BT vs. surgery alone, there was no significant difference in bone fracture risk between the two cohorts ($p = 0.2$) (34). The risk of bone fracture is increased with periosteal stripping or bone resection.

Chronic neuropathy is reported in 0–10.1%, but overall it is not believed to be increased by BT (10, 34, 45).

Special considerations

Recurrent cancer after prior EBRT

BT has been described for treatment of recurrent sarcomas in a previously irradiated field. There is some controversy as to the benefit of reirradiation. Torres *et al.* reported on their retrospective series of WLE with or without further radiation in 62 patients. Twenty-five patients underwent WLE alone and 37 WLE and radiation. Thirty-three of these patients underwent a single-plane BT implant. Radiation doses were 45–64 Gy. The 5-year DFS was 65% and LC 51%. Radiation, however, was not associated with improved LC, and they noted significant toxicity: 80% reoperation rate in the combined cohort vs. 17% with surgery alone ($p < 0.001$). The amputation rate, however, was 35% in the surgery-only group and 11% in the irradiated group ($p = 0.05$) (59). Catton *et al.* (60) reported on 25 patients with recurrent sarcoma, 11 underwent conservative surgery alone, and 10 conservative surgery and irradiation (six cases BT only, one BT and EBRT, three EBRT only). The mean dose was 49.5 Gy (35–65 Gy). The overall LC at 24 months was 91%, but LC was better when radiation therapy was added to the surgery (36% vs. 100%). Wound healing complications occurred in 60% of the cases. In spite of the wound healing problems, 70% were ultimately felt to have good functional outcome. Pearlstone *et al.* (61) also reported on a series of 26 patients treated for local recurrence with a mean BT dose of 47.2 Gy. Local recurrence-free survival at 5 years was 52% and DFS 33%. The reoperation rate was only 15%, possible because 50% of the patients had up-front tissue transfer grafts.

Retroperitoneal sarcoma

Retroperitoneal sarcomas present a major therapeutic challenge because of the high rate of local recurrence and the proximity of the OAR, which include the small bowel, kidneys, liver, stomach, and spinal cord. Radiation therapy appears to improve LC in patients with retroperitoneal sarcomas, and it is most commonly given with preoperative EBRT (62). Intraoperative radiation (IORT), using electron beam or HDR BT, has been evaluated as a means to improve LC (63–66). The delivery of IORT is outside the scope of this article. The success however of IORT led to evaluations of postoperative BT in this population.

The Princess Margaret Hospital group published their experience of 46 patients who underwent gross total resection with 45 Gy preoperative EBRT (41 patients) with or without postoperative BT boost of 25 Gy (23 patients). They found BT to the upper abdomen to be associated with significant toxicity leading to two deaths (4.3%). This led the authors to restrict the use of BT to only the lower abdomen (67). Such treatment approaches should be individualized to the patient, and their use may depend on the skill and expertise of the brachytherapist and surgeon.

Plaque and superficial BT

Dural plaque BT for spine or paraspinal sarcomas has been described by the Massachusetts General Hospital group using yttrium-90 or phosphorus-32 as a boost to EBRT (68). They described a technique of designing specific semi-cylindrical plaques based on dural areas at risk as measured on preoperative MRI. The plaques are then placed intraoperatively to deliver 7.5–15 Gy and then removed. LC was achieved in 22 of 33 patients (66%) with minimal toxicity.

BT may be used to treat superficial sarcomas such as angiosarcomas of the scalp and other sites and for Kaposi sarcoma (69–71).

Permanent seed implants

Permanent seeds are a recognized BT technique that may be applicable to sarcomas in selected circumstances, particularly when target volumes are small such as in cases of head and neck, central nervous system, or other confined tumor locations. Iodine-125 (^{125}I) mesh implants as used for non-small cell lung cancer (72) have been described for various thoracic malignancies (73, 74). There is, however, no consensus about the applicability of mesh implants in treatment of STSs.

Pediatrics

The most common pediatric sarcomas are gynecologic and genitourinary rhabdomyosarcomas and STS (75). In the pediatric population, BT, where applicable, can be used to minimize dose to normal tissue to mitigate the long-term toxicities of radiation, including growth retardation, effects on organ function, and theoretically decrease the secondary malignancy risk. Other advantages of BT are the decreased treatment time and to avoid or minimize the need for daily sedation. In some cases, it may be used as the only form of radiation therapy, and in others, it may need to be combined with EBRT. Both LDR and HDR have been described in the pediatric literature (44, 76–83). LDR temporary implants may incorporate the use of low-energy sources (such as ^{125}I used alone or in combination with ^{192}Ir) to improve dosimetry and enhance radiation safety (83). The use of temporary ^{125}I greatly facilitates radiation protection of family members and healthcare

personnel who remain in close contact with the pediatric patient during treatment. The lower tissue penetration characteristics of ^{125}I can also be used to reduce radiation doses to adjacent organs. HDR BT altogether eliminates radiation exposure to nurses, family, and other medical personnel caring for infants and children. Because of the nature of BT in the pediatric patient, we recommend that BT be performed in centers with the necessary expertise.

Discussion

Radiation therapy improves LC in patients undergoing conservative surgery for STS. Selected cases with favorable lesions (small [<5 cm] superficial tumors or small deep tumors) that can be excised with clear margins (>1 cm) may be treated with surgery alone. Radiation therapy should be offered to patients with STS who are at risk of local recurrence. It can be administered as EBRT or BT or in combination. The advantages of BT are the localized nature of the radiation and relative dose sparing of the surrounding tissue. EBRT has the benefit of being able to encompass large volumes of tissue at risk of recurrence, and it is not limited by anatomic constraints. The additional risks of BT are surgical as both BT and EBRT can produce acute or chronic radiation-induced side effects.

There are no randomized data or consensus on whether it is preferable to use EBRT alone, BT monotherapy, or BT as a boost in the various clinical settings described in this article. The clinician must use the modality or combination of modalities that are most familiar to the treatment team and suitable to the patient.

In the MSKCC randomized trial, BT monotherapy was described as useful for high-grade lesions with favorable surgical findings. This single-institution study did not demonstrate a reduction in local recurrence for low-grade STS, some of which were large and locally recurrent; this finding has not been reported by other investigators. We believe, patients with larger (>5 cm), high grade, or incompletely resected disease (microscopic or gross positive margins) must be treated with sufficient margins and doses high enough to achieve local tumor control. In this setting, depending on morbidity and logistic considerations, BT boost may be preferable to BT alone. In cases of recurrent cancer, but without previous radiation therapy, it is recommended that BT be used in conjunction with EBRT.

In a noteworthy publication MSKCC used their prospective BT database to compare BT monotherapy to EBRT alone in the form of intensity-modulated radiation therapy (IMRT). Despite having more adverse features including positive margins in the IMRT cohort, the LC was better (91% IMRT vs. 81% BT, $p = 0.04$) (84). This LC rate in the IMRT cohort is similar to some studies using a combination of EBRT and BT (28, 38, 40, 41, 51). The authors believe that these results merit further investigations that compare or combine the BT and IMRT.

Conclusion

BT is a useful component of the treatment of STS. The radiation oncologist and surgeon must work closely together to determine the extent of disease and to correctly place and stabilize the BT catheters for optimal results. Three-dimensional simulation and treatment planning are required for defining the clinical treatment volume and to identify dose constraints to OAR. Depending on the type and extent of surgery, it is usually advisable to wait several days to allow wound healing before starting treatment. LDR, HDR, and PDR are valid source loading alternatives. There are more clinical outcome studies with LDR, but HDR offers the potential for improved dosimetry as well as new and creative dose and fractionations that might improve therapeutic ratios. Radiation safety is better with PDR and HDR remote afterloading. The advantages of BT are a more targeted dose distribution, the low integral dose, and shorter treatment times. Adjuvant BT monotherapy is appropriate for lesions of the trunk and extremity after complete surgical resection with negative margins. BT alone is also particularly helpful in pediatric and previously irradiated patients. Other cases, such as large, incompletely resected, or recurrent (not previously irradiated) lesions, may be best managed with a combination of BT and EBRT.

References

- [1] Tepper JE, Suit HD. The role of radiation therapy in the treatment of sarcoma of soft tissue. *Cancer Invest* 1985;3:587–592.
- [2] Rosenberg SA, Tepper J, Glatstein E, et al. The treatment of soft-tissue sarcomas of the extremities: Prospective randomized evaluations of (1) limb-sparing surgery plus radiation therapy compared with amputation and (2) the role of adjuvant chemotherapy. *Ann Surg* 1982;196:305–315.
- [3] Lindberg RD, Martin RG, Romsdahl MM, et al. Conservative surgery and postoperative radiotherapy in 300 adults with soft-tissue sarcomas. *Cancer* 1981;47:2391–2397.
- [4] Baldini EH, Goldberg J, Jenner C, et al. Long-term outcomes after function-sparing surgery without radiotherapy for soft tissue sarcoma of the extremities and trunk. *J Clin Oncol* 1999;17:3252–3259.
- [5] Pisters PW, Pollock RE, Lewis VO, et al. Long-term results of prospective trial of surgery alone with selective use of radiation for patients with T1 extremity and trunk soft tissue sarcomas. *Ann Surg* 2007;246:675–681. discussion 681–682.
- [6] Yang JC, Chang AE, Baker AR, et al. Randomized prospective study of the benefit of adjuvant radiation therapy in the treatment of soft tissue sarcomas of the extremity. *J Clin Oncol* 1998;16:197–203.
- [7] Brennan MF, Hilaris B, Shiu MH, et al. Local recurrence in adult soft-tissue sarcoma. A randomized trial of brachytherapy. *Arch Surg* 1987;122:1289–1293.
- [8] Alektiar KM, Leung D, Zelefsky MJ, et al. Adjuvant brachytherapy for primary high-grade soft tissue sarcoma of the extremity. *Ann Surg Oncol* 2002;9:48–56.
- [9] Alekhteyar KM, Leung DH, Brennan MF, et al. The effect of combined external beam radiotherapy and brachytherapy on local control and wound complications in patients with high-grade soft tissue sarcomas of the extremity with positive microscopic margin. *Int J Radiat Oncol Biol Phys* 1996;36:321–324.
- [10] Petera J, Soumarova R, Ruzickova J, et al. Perioperative hyperfractionated high-dose rate brachytherapy for the treatment of soft tissue sarcomas: Multicentric experience. *Ann Surg Oncol* 2010;17:206–210.
- [11] Demetri GD, Pollock R, Baker L, et al. NCCN sarcoma practice guidelines. National Comprehensive Cancer Network. *Oncology (Williston Park)* 1998;12:183–218.
- [12] Schwab JH, Boland PJ, Antonescu C, et al. Spinal metastases from myxoid liposarcoma warrant screening with magnetic resonance imaging. *Cancer* 2007;110:1815–1822.
- [13] Smith R, Demmy TL. Pulmonary metastasectomy for soft tissue sarcoma. *Surg Oncol Clin N Am* 2012;21:269–286.
- [14] Pfannschmidt J, Hoffmann H, Schneider T, et al. Pulmonary metastasectomy for soft tissue sarcomas: Is it justified? *Recent Results Cancer Res* 2009;179:321–336.
- [15] Jablons D, Steinberg SM, Roth J, et al. Metastasectomy for soft tissue sarcoma. Further evidence for efficacy and prognostic indicators. *J Thorac Cardiovasc Surg* 1989;97:695–705.
- [16] Blackmon SH, Shah N, Roth JA, et al. Resection of pulmonary and extrapulmonary sarcomatous metastases is associated with long-term survival. *Ann Thorac Surg* 2009;88:877–884. discussion 884–885.
- [17] Marudanayagam R, Sandhu B, Perera MT, et al. Liver resection for metastatic soft tissue sarcoma: An analysis of prognostic factors. *Eur J Surg Oncol* 2011;37:87–92.
- [18] Rehders A, Peiper M, Stoecklein NH, et al. Hepatic metastasectomy for soft-tissue sarcomas: Is it justified? *World J Surg* 2009;33:111–117.
- [19] Rydholm A, Gustafson P, Rooser B, et al. Limb-sparing surgery without radiotherapy based on anatomic location of soft tissue sarcoma. *J Clin Oncol* 1991;9:1757–1765.
- [20] Cahlon O, Brennan MF, Jia X, et al. A postoperative nomogram for local recurrence risk in extremity soft tissue sarcomas after limb-sparing surgery without adjuvant radiation. *Ann Surg* 2012;255:343–347.
- [21] Alektiar KM, Velasco J, Zelefsky MJ, et al. Adjuvant radiotherapy for margin-positive high-grade soft tissue sarcoma of the extremity. *Int J Radiat Oncol Biol Phys* 2000;48:1051–1058.
- [22] Andrews SF, Anderson PR, Eisenberg BL, et al. Soft tissue sarcomas treated with postoperative external beam radiotherapy with and without low-dose-rate brachytherapy. *Int J Radiat Oncol Biol Phys* 2004;59:475–480.
- [23] San Miguel I, San Julian M, Cambeiro M, et al. Determinants of toxicity, patterns of failure, and outcome among adult patients with soft tissue sarcomas of the extremity and superficial trunk treated with greater than conventional doses of perioperative high-dose-rate brachytherapy and external beam radiotherapy. *Int J Radiat Oncol Biol Phys* 2011;81:e529–e539.
- [24] Itami J, Sumi M, Beppu Y, et al. High-dose rate brachytherapy alone in postoperative soft tissue sarcomas with close or positive margins. *Brachytherapy* 2010;9:349–353.
- [25] Chun M, Kang S, Kim BS, et al. High dose rate interstitial brachytherapy in soft tissue sarcoma: Technical aspects and results. *Jpn J Clin Oncol* 2001;31:279–283.
- [26] Alektiar KM, Brennan MF, Singer S. Influence of site on the therapeutic ratio of adjuvant radiotherapy in soft-tissue sarcoma of the extremity. *Int J Radiat Oncol Biol Phys* 2005;63:202–208.
- [27] Pohar S, Haq R, Liu L, et al. Adjuvant high-dose-rate and low-dose-rate brachytherapy with external beam radiation in soft tissue sarcoma: A comparison of outcomes. *Brachytherapy* 2007;6:53–57.
- [28] Llacer C, Delannes M, Minsat M, et al. Low-dose intraoperative brachytherapy in soft tissue sarcomas involving neurovascular structure. *Radiother Oncol* 2006;78:10–16.
- [29] Rohde RS, Puhaindran ME, Morris CD, et al. Complications of radiation therapy to the hand after soft tissue sarcoma surgery. *J Hand Surg Am* 2010;35:1858–1863.
- [30] Nag S, Shasha D, Janjan N, et al., American Brachytherapy Society. The American Brachytherapy Society recommendations for

- brachytherapy of soft tissue sarcomas. *Int J Radiat Oncol Biol Phys* 2001;49:1033–1043.
- [31] Haas RL, Delaney TF, O'Sullivan B, et al. Radiotherapy for management of extremity soft tissue sarcomas: Why, when, and where? *Int J Radiat Oncol Biol Phys* 2012;84:572–580.
- [32] Demanes DJ, Friedman JM, Park SJ, et al. Brachytherapy catheter spacing and stabilization technique. *Brachytherapy* 2012;11:392–397.
- [33] Habrand JL, Gerbaulet A, Pejovic MH, et al. Twenty years experience of interstitial iridium brachytherapy in the management of soft tissue sarcomas. *Int J Radiat Oncol Biol Phys* 1991;20:405–411.
- [34] Alektiar KM, Zelefsky MJ, Brennan MF. Morbidity of adjuvant brachytherapy in soft tissue sarcoma of the extremity and superficial trunk. *Int J Radiat Oncol Biol Phys* 2000;47:1273–1279.
- [35] Cionini L, Marzano S, Olmi P. Soft tissue sarcomas: Experience with intraoperative brachytherapy in the conservative management. *Ann Oncol* 1992;3:S63–S66.
- [36] Schray MF, Gunderson LL, Sim FH, et al. Soft tissue sarcoma. Integration of brachytherapy, resection, and external irradiation. *Cancer* 1990;66:451–456.
- [37] Shiu MH, Hilaris BS, Harrison LB, et al. Brachytherapy and function-saving resection of soft tissue sarcoma arising in the limb. *Int J Radiat Oncol Biol Phys* 1991;21:1485–1492.
- [38] Delannes M, Thomas L, Martel P, et al. Low-dose-rate intraoperative brachytherapy combined with external beam irradiation in the conservative treatment of soft tissue sarcoma. *Int J Radiat Oncol Biol Phys* 2000;47:165–169.
- [39] Rosenblatt E, Meushar N, Bar-Deroma R, et al. Interstitial brachytherapy in soft tissue sarcomas: The Rambam experience. *Isr Med Assoc J* 2003;5:547–551.
- [40] Beltrami G, Rudiger HA, Mela MM, et al. Limb salvage surgery in combination with brachytherapy and external beam radiation for high-grade soft tissue sarcomas. *Eur J Surg Oncol* 2008;34:811–816.
- [41] Mierzwa ML, McCluskey CM, Barrett WL, et al. Interstitial brachytherapy for soft tissue sarcoma: A single institution experience. *Brachytherapy* 2007;6:298–303.
- [42] Laskar S, Bahl G, Puri A, et al. Perioperative interstitial brachytherapy for soft tissue sarcomas: Prognostic factors and long-term results of 155 patients. *Ann Surg Oncol* 2007;14:560–567.
- [43] Chaudhary AJ, Laskar S, Badhwar R. Interstitial brachytherapy in soft tissue sarcomas. The Tata Memorial Hospital experience. *Strahlenther Onkol* 1998;174:522–528.
- [44] Laskar S, Bahl G, Ann Muckaden M, et al. Interstitial brachytherapy for childhood soft tissue sarcoma. *Pediatr Blood Cancer* 2007;49:649–655.
- [45] Kubo T, Sugita T, Shimose S, et al. Nerve tolerance to high-dose-rate brachytherapy in patients with soft tissue sarcoma: A retrospective study. *BMC Cancer* 2005;5:79.
- [46] Emory CL, Montgomery CO, Potter BK, et al. Early complications of high-dose-rate brachytherapy in soft tissue sarcoma: A comparison with traditional external-beam radiotherapy. *Clin Orthop Relat Res* 2012;470:751–758.
- [47] Koizumi M, Inoue T, Yamazaki H, et al. Perioperative fractionated high-dose rate brachytherapy for malignant bone and soft tissue tumors. *Int J Radiat Oncol Biol Phys* 1999;43:989–993.
- [48] Nag S, Tippin D, Ruymann FB. Long-term morbidity in children treated with fractionated high-dose-rate brachytherapy for soft tissue sarcomas. *J Pediatr Hematol Oncol* 2003;25:448–452.
- [49] Martinez-Monge R, San Julian M, Amillo S, et al. Perioperative high-dose-rate brachytherapy in soft tissue sarcomas of the extremity and superficial trunk in adults: Initial results of a pilot study. *Brachytherapy* 2005;4:264–270.
- [50] Aronowitz JN, Pohar SS, Liu L, et al. Adjuvant high dose rate brachytherapy in the management of soft tissue sarcoma: A dose-toxicity analysis. *Am J Clin Oncol* 2006;29:508–513.
- [51] Lazzaro G, Lazzari R, Pelosi G, et al. Pulsed dose-rate perioperative interstitial brachytherapy for soft tissue sarcomas of the extremities and skeletal muscles of the trunk. *Ann Surg Oncol* 2005;12:935–942.
- [52] Muhic A, Hovgaard D, Mork PM, et al. Local control and survival in patients with soft tissue sarcomas treated with limb sparing surgery in combination with interstitial brachytherapy and external radiation. *Radiother Oncol* 2008;88:382–387.
- [53] Reece GP, Schusterman MA, Pollock RE, et al. Immediate versus delayed free-tissue transfer salvage of the lower extremity in soft tissue sarcoma patients. *Ann Surg Oncol* 1994;1:11–17.
- [54] Serletti JM, Carras AJ, O'Keefe RJ, et al. Functional outcome after soft-tissue reconstruction for limb salvage after sarcoma surgery. *Plast Reconstr Surg* 1998;102:1576–1583. discussion 1584–1585.
- [55] Aflatoon K, Manoso MW, Deune EG, et al. Brachytherapy tubes and free tissue transfer after soft tissue sarcoma resection. *Clin Orthop Relat Res* 2003;415:248–253.
- [56] Spierer MM, Alektiar KM, Zelefsky MJ, et al. Tolerance of tissue transfers to adjuvant radiation therapy in primary soft tissue sarcoma of the extremity. *Int J Radiat Oncol Biol Phys* 2003;56:1112–1116.
- [57] Heller L, Ballo MT, Cormier JN, et al. Staged reconstruction for resection wounds in sarcoma patients treated with brachytherapy. *Ann Plast Surg* 2008;60:58–63.
- [58] Goel V, Goel A, Gupta N, et al. Flap reconstruction and interstitial brachytherapy in nonextremity soft tissue sarcoma. *J Cancer Res Ther* 2007;3:105–107.
- [59] Torres MA, Ballo MT, Butler CE, et al. Management of locally recurrent soft-tissue sarcoma after prior surgery and radiation therapy. *Int J Radiat Oncol Biol Phys* 2007;67:1124–1129.
- [60] Catton C, Davis A, Bell R, et al. Soft tissue sarcoma of the extremity. Limb salvage after failure of combined conservative therapy. *Radiother Oncol* 1996;41:209–214.
- [61] Pearlstone DB, Janjan NA, Feig BW, et al. Re-resection with brachytherapy for locally recurrent soft tissue sarcoma arising in a previously radiated field. *Cancer J Sci Am* 1999;5:26–33.
- [62] Van De Voorde L, Delrue L, van Eijkeren M, et al. Radiotherapy and surgery—An indispensable duo in the treatment of retroperitoneal sarcoma. *Cancer* 2011;117:4355–4364.
- [63] Youssef E, Fontanesi J, Mott M, et al. Long-term outcome of combined modality therapy in retroperitoneal and deep-trunk soft-tissue sarcoma: Analysis of prognostic factors. *Int J Radiat Oncol Biol Phys* 2002;54:514–519.
- [64] Gieschen HL, Spiro IJ, Suit HD, et al. Long-term results of intraoperative electron beam radiotherapy for primary and recurrent retroperitoneal soft tissue sarcoma. *Int J Radiat Oncol Biol Phys* 2001;50:127–131.
- [65] Alektiar KM, Hu K, Anderson L, et al. High-dose-rate intraoperative radiation therapy (HDR-IORT) for retroperitoneal sarcomas. *Int J Radiat Oncol Biol Phys* 2000;47:157–163.
- [66] Sindelar WF, Tepper JE, Kinsella TJ, et al. Late effects of intraoperative radiation therapy on retroperitoneal tissues, intestine, and bile duct in a large animal model. *Int J Radiat Oncol Biol Phys* 1994;29:781–788.
- [67] Jones JJ, Catton CN, O'Sullivan B, et al. Initial results of a trial of preoperative external-beam radiation therapy and postoperative brachytherapy for retroperitoneal sarcoma. *Ann Surg Oncol* 2002;9:346–354.
- [68] DeLaney TF, Chen GT, Mauceri TC, et al. Intraoperative dural irradiation by customized 192iridium and 90yttrium brachytherapy plaques. *Int J Radiat Oncol Biol Phys* 2003;57:239–245.
- [69] Evans MDC, Yassa M, Podgorsak EB, et al. Surface applicators for high dose rate brachytherapy in AIDS-related Kaposi's sarcoma. *Int J Radiat Oncol Biol Phys* 1997;39:769–774.
- [70] Nakamura R, Harada S, Obara T, et al. Iridium-192 brachytherapy for hemorrhagic angiosarcoma of the scalp: A case report. *Jpn J Clin Oncol* 2003;33:198–201.

- [71] Syndikus I, Vinall A, Rogers P, et al. High dose rate Microselectron moulds for Kaposi sarcoma of the palate. *Radiother Oncol* 1997;42: 167–170.
- [72] Voynov G, Heron DE, Lin CJ, et al. Intraoperative 125I Vicryl mesh brachytherapy after sublobar resection for high-risk stage I non-small cell lung cancer. *Brachytherapy* 2005;4:278–285.
- [73] Mutyala S, Stewart A, Khan AJ, et al. Permanent iodine-125 interstitial planar seed brachytherapy for close or positive margins for thoracic malignancies. *Int J Radiat Oncol Biol Phys* 2010;76: 1114–1120.
- [74] Raut C, Albert M. Soft tissue sarcoma brachytherapy. In: Devlin PM, editor. *Brachytherapy applications and techniques*. 1st ed. Philadelphia, PA: Lippincott Williams & Wilkins; 2006. p. 269.
- [75] Haie-Meder C, Martelli H, Dumas I, et al. Brachytherapy in paediatric sarcoma. *Bull Cancer* 2011;98:549–557.
- [76] Martinez-Monge R, Garran C, Cambeiro M, et al. Feasibility report of conservative surgery, perioperative high-dose-rate brachytherapy (PHDRB), and low-to-moderate dose external beam radiation therapy (EBRT) in pediatric sarcomas. *Brachytherapy* 2004;3: 196–200.
- [77] Nag S, Martinez-Monge R, Ruymann F, et al. Innovation in the management of soft tissue sarcomas in infants and young children: High-dose-rate brachytherapy. *J Clin Oncol* 1997;15:3075–3084.
- [78] Nag S, Tippin D, Ruymann FB. Intraoperative high-dose-rate brachytherapy for the treatment of pediatric tumors: The Ohio State University experience. *Int J Radiat Oncol Biol Phys* 2001;51:729–735.
- [79] Heinzelmann F, Thorwarth D, Lamprecht U, et al. Comparison of different adjuvant radiotherapy approaches in childhood bladder/prostate rhabdomyosarcoma treated with conservative surgery. *Strahlenther Onkol* 2011;187:715–721.
- [80] Martelli H, Haie-Meder C, Branchereau S, et al. Conservative surgery plus brachytherapy treatment for boys with prostate and/or bladder neck rhabdomyosarcoma: A single team experience. *J Pediatr Surg* 2009;44:190–196.
- [81] Magne N, Oberlin O, Martelli H, et al. Vulval and vaginal rhabdomyosarcoma in children: Update and reappraisal of Institut Gustave Roussy brachytherapy experience. *Int J Radiat Oncol Biol Phys* 2008;72:878–883.
- [82] Viani GA, Novaes PE, Jacinto AA, et al. High-dose-rate brachytherapy for soft tissue sarcoma in children: A single institution experience. *Radiat Oncol* 2008;19:9.
- [83] Merchant TE, Parsh N, del Valle PL. Brachytherapy for pediatric soft-tissue sarcoma. *Int J Radiat Oncol Biol Phys* 2000;46:427–432.
- [84] Alektiar KM, Brennan MF, Singer S. Local control comparison of adjuvant brachytherapy to intensity-modulated radiotherapy in primary high-grade sarcoma of the extremity. *Cancer* 2011;117: 3229–3234.