

CLINICAL INVESTIGATION

GEC-ESTRO (ACROP)—ABS—CBG Consensus Brachytherapy Target Definition Guidelines for Recurrent Endometrial and Cervical Tumors in the Vagina



Mitchell Kamrava, MD, MHDS,* Eric Leung, MD,[†] Francois Bachand, MD,[‡] Sushil Beriwal, MD, MBA,[§] Cyrus Chargari, MD, PhD,^{||} David D'Souza, MD,[¶] Beth Erickson, MD,[#] Lars Fokdal, MD, PhD,^{**} Kathy Han, MD,^{††} Matthew Harkenrider, MD,^{‡‡} Lilie Lin, MD,^{§§} Umesh Mahantshetty, MD,^{|||} Nicole Nesvacil, PhD,^{¶¶} Ananth Ravi, PhD,[†] Max Schmid, MD,^{¶¶} Eric Vigneault, MD,^{##} Henrike Westerveld, MD, PhD,^{***} Catheryn Yashar, MD,^{†††} and Remi Nout, MD, PhD^{†††}

*Cedars Sinai Medical Center, Los Angeles, California; [†]Sunnybrook Odette Cancer Center, Ontario; [‡]BC Cancer, British Columbia, Canada; [§]Allegheny Health Network, Pittsburgh, Pennsylvania and Varian Medical Systems, Palo Alto, California; ^{||}Gustave Roussy Comprehensive Cancer Center, Villejuif, France; [¶]London Health Sciences Centre, Ontario, Canada; [#]Medical College of Wisconsin, Milwaukee, Wisconsin; ^{**}Aarhus University Hospital, Aarhus, Denmark; ^{††}Princess Margaret Cancer Centre, University Health Network, University of Toronto, Ontario, Canada; ^{‡‡}Loyola University Chicago, Stritch School of Medicine, Maywood, Illinois; ^{§§}MD Anderson Cancer Center, Houston, Texas; ^{|||}Tata Memorial Hospital, Mumbai, India; ^{¶¶}Department of Radiation Oncology, Comprehensive Cancer Center, Medical University of Vienna, Austria; ^{##}Centre Hospitalier Universitaire de Québec, Québec, Canada; ^{***}Amsterdam University Medical Centers, Amsterdam, the Netherlands; ^{†††}University of California San Diego, San Diego, California; and ^{†††}Erasmus MC Cancer Institute, University Medical Center Rotterdam, the Netherlands

Received Jul 14, 2022; Accepted for publication Sep 13, 2022

Purpose: Representatives from the Gynecologic Groupe European de Curietherapie—European Society for Radiation Therapy and Oncology (GYN GEC-ESTRO), the American Brachytherapy Society (ABS), and the Canadian Brachytherapy Group (CBG) met to develop international consensus recommendations for target definitions for image-guided adaptive brachytherapy for vaginal recurrences of endometrial or cervical cancer.

Methods and Materials: Seventeen radiation oncologists and 2 medical physicists participated. Before an in-person meeting each participant anonymously contoured 3 recurrent endometrial/cervical cancer cases. Participants contoured the residual gross primary tumor volume (GTV-T_{res}), a high-risk clinical target volume (CTV-T_{HR}), and an intermediate-risk clinical target volume (CTV-T_{IR}), on T2-weighted magnetic resonance images (MRIs). All contours were drawn using Falcon EduCase. Contours were reviewed at an in-person meeting during which a consensus document was created defining agreed-upon target definitions (Trial 1). After establishing these definitions, the group was sent one of the cases again (recurrent cervical cancer vaginal recurrence) and asked to contour the targets again (Trial 2).

The Computerized Environment for Radiation Research (CERR) software (The Mathworks, Natwick, MA) was used to analyze the contours. Kappa statistics were generated to assess level of agreement between contours. A conformity index (CI), defined as the ratio between the intersection and union volume of a given pair of contours, was calculated. A simultaneous truth and performance level estimation (STAPLE) contour was created for the CTV-T_{HR} and CTV-T_{IR} for the postmeeting case.

Corresponding author: Mitchell Kamrava, MD; E-mail: Mitchell.Kamrava@cshs.org

Mitchell Kamrava and Eric Leung made equal contributions to this study.

Disclosures for Mitchell Kamrava: Advisory board fees Theragenics, DSMB Alessa, DSMB GT Medical Technologies, Book royalties Springer.

Research data will be shared upon request to the corresponding author.

Supplementary material associated with this article can be found in the online version at [doi:10.1016/j.ijrobp.2022.09.072](https://doi.org/10.1016/j.ijrobp.2022.09.072).

Results: Consensus definitions for GTV- T_{res} , CTV- T_{HR} , and CTV- T_{IR} were established. Kappa statistics (Trial 1/Trial 2) for GTV- T_{res} , CTV- T_{HR} , and CTV- T_{IR} were 0.536/0.583, 0.575/0.743 and 0.522/0.707. Kappa statistics for Trial 2 for the CTV- T_{HR} and CTV- T_{IR} showed “substantial” agreement while the GTV- T_{res} remained at moderate agreement.

Conclusions: This consensus provides recommendations to facilitate future collaborations for MRI-guided adaptive brachytherapy target definitions in endometrial/cervical vaginal recurrences. © 2022 Elsevier Inc. All rights reserved.

Introduction

Vaginal recurrences from endometrial or cervical cancer pose clinical challenges. Endometrial cancer recurrences commonly arise in the posthysterectomy surgical scar, but may additionally develop at other sites in the vaginal wall.¹⁻⁵ Multifocal spread can also be observed in patients with extensive lymph vascular space involvement (LVSI) or more aggressive histologies (eg, serous cancer).⁶ Prognosis is related to the original risk-group classification, with the low-grade endometrioid type having a favorable prognosis compared with high-grade or nonendometrioid tumors.¹ More recent data suggest molecular risk factors, such as p53 or mismatch repair deficient (MMRd), should also be considered.⁷ For cervical cancer, central recurrences are observed after radical hysterectomy with risk factors for recurrence including size of the primary tumor, depth of invasion, presence of LVSI, and nonsquamous histologies.^{2,3} Finally, a unique challenge in these cases is the complexities of reirradiation for recurrences in women who received previous radiation therapy as part of the initial adjuvant management of their primary tumor.⁸

Clinical management of these recurrences can be challenging, as their location in the central pelvis can result in significant symptoms and treatment-related morbidities. Surgery is an option but often entails an exenteration procedure to completely resect disease, with associated significant morbidity. Therefore, organ-preserving approaches with external radiation and brachytherapy play important roles in the treatment of these tumors. The availability of modern computed tomography/magnetic resonance imaging (CT/MRI)-compatible brachytherapy applicators has enabled the implementation of volumetric (3-dimensional) image-guided adaptive brachytherapy (IGABT). In particular, multicatheter intracavitary (eg, multichannel cylinder) and combined interstitial-intracavitary techniques have allowed improved target coverage and organ at risk sparing in cases of asymmetrical lateralized and complex anatomic target volumes.

Although significant guidance regarding brachytherapy target volume definition for cervical and primary vaginal cancer has been published, similar guidance is not available for recurrent endometrial/cervical vaginal lesions. For locally advanced cervical cancer, IGABT is the current standard of care, and the cancer cell density-based adaptive target concept developed by the Gynecologic Groupe Européen de Curiothérapie—European Society for Radiation Therapy and Oncology (GYN GEC-ESTRO) has been endorsed in the recent International Commission on Radiological Units and Measurements' (ICRU's) ICRU-89 report.⁹ Only recently was

an IGABT target concept for primary vaginal cancer published.¹⁰ When reviewing the details of published image-guided brachytherapy series for primary vaginal cancer and recurrent endometrial/cervical vaginal tumors, often the exact target volume definition is not clear and there is wide variation in those that are available (Table E1 and Table E2).¹¹⁻²² Compared with the treatment of locally advanced cervical cancer, in which the high-risk clinical target volume always includes at minimum the entire cervix, in vaginal cancer only the residual gross tumor volume and surrounding pathologic tissue are included in the high dose volume, while more variation exists regarding the intermediate dose volume. This is related to the increased morbidity that comes with treating the entire vagina, especially toward the lower third. Another specific consideration that varies from cervical cancer is there are rare cases in which a patient has a complete clinical and radiographic response after initial external beam radiation therapy (EBRT) of a small superficial tumor. Defining a target volume in these cases presents a challenge. Furthermore, there are some differences between primary vaginal and recurrent endometrial/cervical vaginal lesions. These include histologies with varying natural histories and related patterns of infiltration and spread (ie, clear cell, serous cancer), more distal recurrences for patients with endometrial cancer who have histories of lymphovascular invasion in their primary tumor, plaque-like or multifocal recurrences, and posthysterectomy anatomic issues related to the surgical scar and bowel sitting superior to the vaginal cuff.²³

Given the variability in target volume definition in the limited published literature, and the specific considerations that should be considered for vaginal recurrences compared with primary vaginal cancer, an international effort was made to develop consensus brachytherapy target recommendations. Representative members from GEC-ESTRO, the American Brachytherapy Society (ABS), and the Canadian Brachytherapy Group (CBG) convened to establish recommendations for defining IGABT clinical target volumes at the time of brachytherapy for recurrent endometrial/cervical cancers in the vagina.

Methods

Representatives (17 radiation oncologists and 2 medical physicists) from Gynecologic GEC-ESTRO, ABS, and CBG participated. Before an in-person meeting, each participant was asked to complete a document describing their institutional practice for contouring and dose recommendations for recurrences of endometrial/cervical cancer in the vagina, including

reirradiation, and to anonymously contour 3 recurrent endometrial/cervical cancer cases. For each of these cases, participants were asked to contour the residual gross primary tumor volume (GTV- T_{res}), a high-risk clinical target volume (CTV- T_{HR}), an intermediate-risk clinical target volume (CTV- T_{IR}), and vagina on T2-weighted MRI images. All contours were drawn using software from Falcon EduCase. An in-person 2-day meeting was convened in 2019 before the annual American Brachytherapy Society Meeting. At this meeting, basic concepts regarding target definition and treatment of vaginal recurrence were discussed and participants' institutional practices and contours were reviewed (Trial 1). After this meeting, a document was created defining the agreed-upon target definitions and circulated to the group for additional comments in October 2020. After this set of revisions, the group was re-sent one of the cases and asked to recontour targets (GTV- T_{res} , CTV- T_{HR} , CTV- T_{IR} , and vagina) based on the agreed-upon definitions (Trial 2). The participants did not have access to their old contours for the recontouring exercise. The case that was sent to the group to recontour was a 54-year-old woman diagnosed with an International Federation of Gynecology and Obstetrics (FIGO) IB1 cervical cancer in 2000 treated definitively with surgery (Fig. 1). She had no indications for adjuvant treatment and subsequently developed a biopsy-proven vaginal recurrence in 2018. On MRI she was noted to have a tumor at the vaginal apex in close proximity to the urethra. It measured $32 \times 41 \times 32$ mm. It was in

close contact with the bladder and at least partially obstructed the left ureter. She was treated with EBRT with concurrent weekly cisplatin to 45 Gy. A repeat MRI, with a Venezia applicator in place for brachytherapy boost, showed a residual tumor measuring $14 \times 16 \times 14$ mm.

The Computerized Environment for Radiation Research (CERR) software (The Mathworks, Natwick, Massachusetts) was used to analyze the contours. Kappa statistics were generated to assess the level of agreement between contours. Based on the work from Landis and Kock, interpretation of kappa values is as follows: 0.0 to 0.2 slight agreement, 0.21 to 0.40 fair agreement, 0.41 to 0.60 moderate agreement, 0.61 to 0.80 substantial agreement, and 0.81 to 1.0 almost perfect or perfect agreement.²⁴ Conformity index (CI), the ratio between the intersection (largest volume common to a pair of contours) and union (smallest volume encompassed by a pair of contours) volume of a given pair of contours, was also calculated.²⁵ A low CI indicates poor agreement and a CI of 1 is perfect agreement. A simultaneous truth and performance level estimation (STAPLE) contour was created for CTV- T_{HR} and CTV- T_{IR} for the postmeeting contouring case as well as sensitivity and specificity statistics.²⁶ The probability that a voxel in the individual expert contour is in the STAPLE contour is represented by sensitivity and the probability that a voxel outside the STAPLE contour is also outside of the expert contour is represented by the specificity.

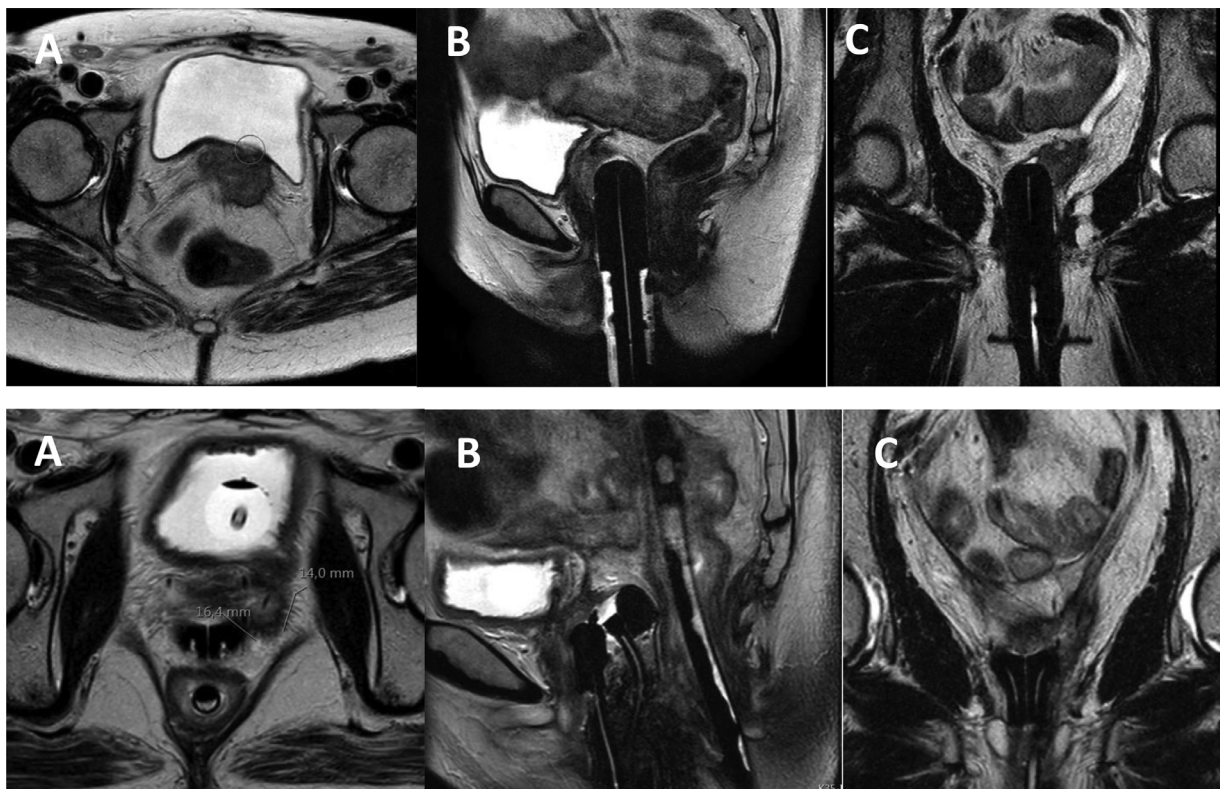


Figure 1. MRI images at time of initial recurrence in Panel 1 (A – axial, B-sagittal, C-coronal) and at the time of brachytherapy in Panel 2 (A- axial, B-sagittal, C-coronal). Residual tumor measurements noted on bottom panel A. Additional details of the case are described in the methods section of the manuscript. Of note, a rectal tube can be seen most clearly on the sagittal image in Panel 2.

Before initializing the guidelines, the committees of the societies involved (GEC-ESTRO, ABS, and CBG) agreed on the methodology and representatives. For GEC-ESTRO, the Advisory Committee for Radiation Oncology Practice approval process and procedures were followed. The final draft was again reviewed by the committees of the societies.

Results

Contouring analysis

For the contouring exercise before the consensus meeting, there was “moderate” agreement among participants using

Landis and Koch’s benchmarks, with Kappa values of 0.536, 0.575, and 0.522 for the GTV-T_{res}, CTV-T_{HR}, and CTV-T_{IR}, respectively (Table E3). Postconsensus meeting, the Kappa values showed “substantial” agreement of 0.743 for CTV-T_{HR} and 0.707 for CTV-T_{IR}. The Kappa value for the GTV-T_{res} remained at moderate agreement of 0.583. Consensus contours were generated using the STAPLE based on an 80% confidence level for GTV-T_{res}, CTV-T_{HR}, and CTV-T_{IR} (Fig. 2). The CI improved between Trial 1 and 2 for the GTV-T_{res}, CTV-T_{HR}, and CTV-T_{IR} as well. However, after Trial 2 the CI for these targets ranged from 0.390 to 0.508. For the vagina contour the kappa improved between Trial 1 and 2; however, after Trial 2 there was still only fair agreement (0.354).

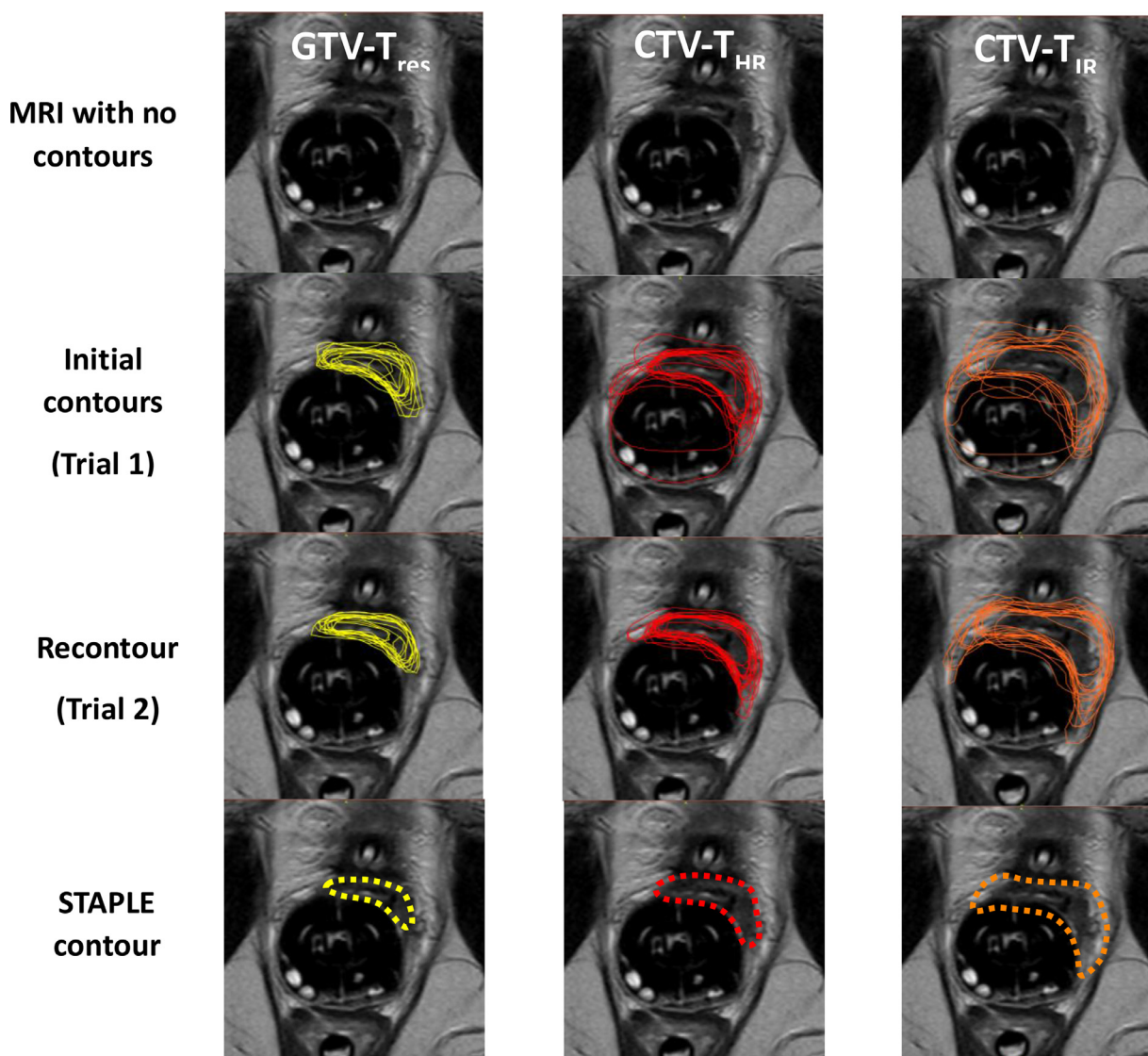


Figure 2. Example of development of consensus contours for GTV-T_{res}, CTV-T_{HR}, and CTV-T_{IR}. A representative axial slice is presented with no contours, initial contours (Trial 1), recontours (Trial 2), and STAPLE contour based on Trial 2 data. The case was a 54-year-old woman diagnosed with a FIGO IB1 cervical cancer treated definitively with surgery and no adjuvant treatment. She developed a biopsy proven vaginal recurrence 8 years later. On MRI she was noted to have a tumor at the vaginal apex. It measured 32 × 41 × 32 mm. She was treated with external beam radiation therapy with concurrent weekly cisplatin to 45 Gy. A repeat MRI, with an applicator in place for brachytherapy boost, showed a residual tumor measuring 14 × 16 × 14 mm.

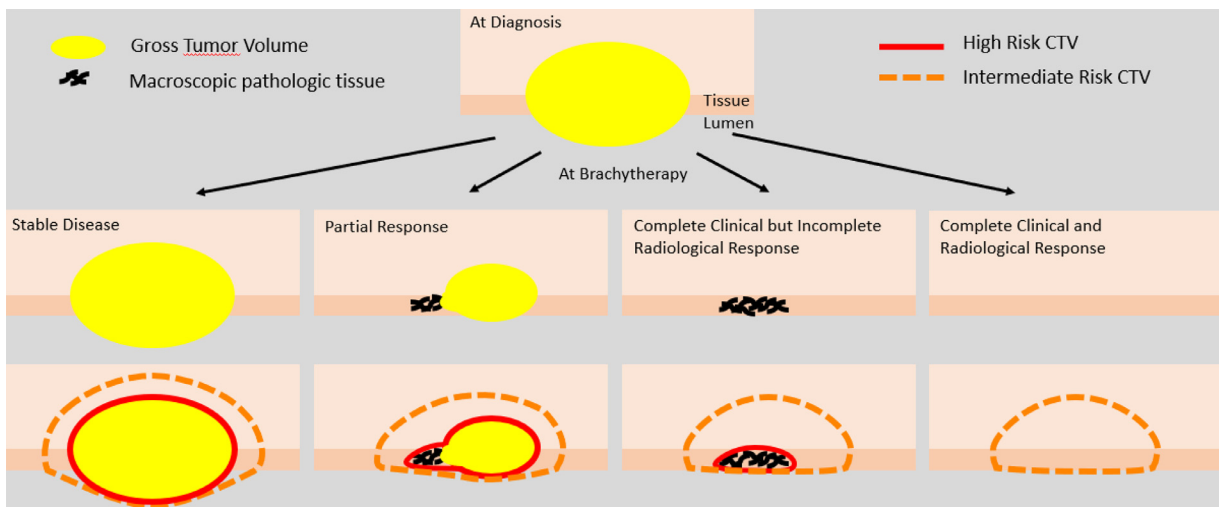


Figure 3. Adaptive target volume concepts for the high and intermediate risk clinical target volumes

Brachytherapy target concept

The basic underlying brachytherapy target concept principles were derived from the GYN GEC-ESTRO target volume concepts put forward for definitive treatment for cervical cancer. This adaptive target concept is based on different response-related target volumes, related to expected cancer cell density and routes of microscopic tumor extension. This concept was updated in the ICRU 89 report to illustrate the adaptive clinical target volume (CTV) concept based on GTV response (Fig. 3). Clinical drawings were recently

developed for primary vaginal cancer, including drawing templates for patients with the uterus in situ or posthysterectomy, and cross-sectional templates, with axial representation for lesions located in the upper 1/3, middle 1/3, and lower 1/3 of the vagina.¹⁰ These clinical drawings should be used to document the original extent of disease at diagnosis and the residual disease at the time of brachytherapy. Another tool that can be helpful in defining the extent of disease is placing marker seeds at the superior-, inferior-, and lateral-most extents of the palpable tumor, which may be larger than the radiographic extent of disease.

Figure with GTV + areas of suspicion

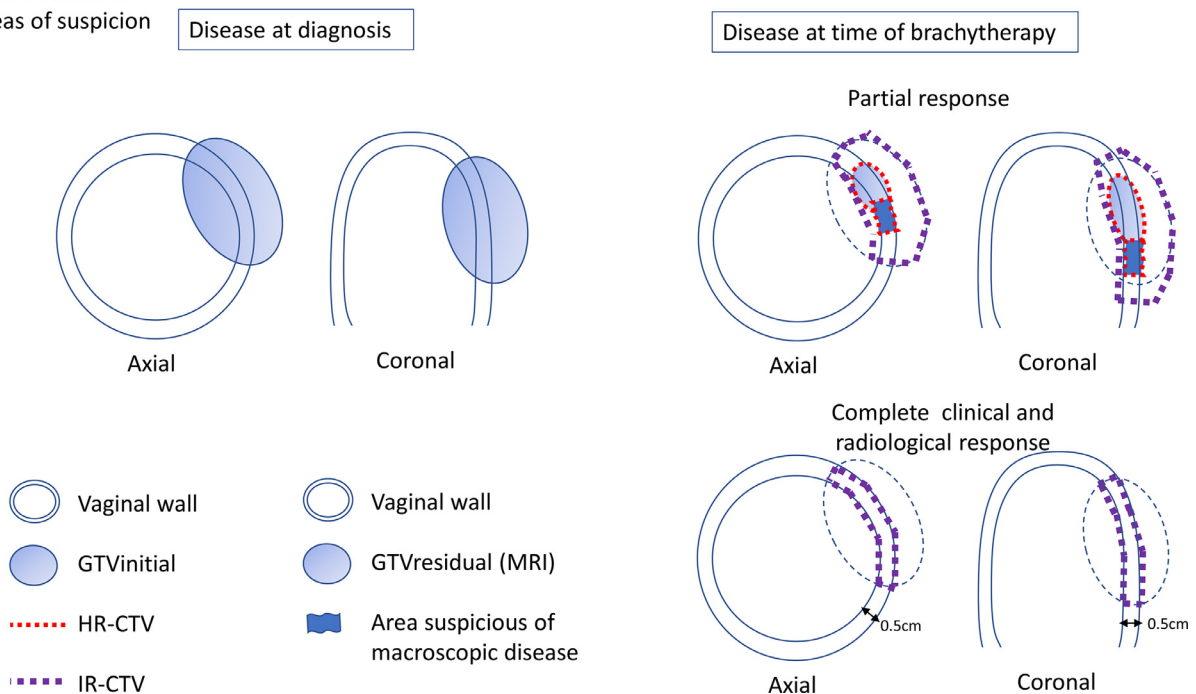


Figure 4.

Residual gross tumor volume (GTV- T_{res})

After an initial course of external beam radiation, most patients will have shrinkage of the initial gross tumor volume (GTV- T_{init}) with some residual disease. The macroscopic gross tumor that remains at the time of brachytherapy, based on clinical examination and imaging, is considered the GTV- T_{res} . The GTV- T_{res} shares similar clinical and imaging characteristics with the GTV- T_{init} . Clinically this is the remaining visible and palpable tumor on gynecologic examination. On imaging, this is visualized on T2-weighted MRI and includes the remaining mass with hyperintense to isointense signal intensity (Fig. 4).

High-risk clinical target tumor volume (CTV- T_{HR})

The CTV- T_{HR} includes the GTV- T_{res} and areas on imaging and/or clinical examination that are concerning for harboring macroscopic pathologic disease. CTV- T_{HR} includes different clinical and imaging characteristics compared with GTV- T_{res} . On clinical examination this includes any abnormal thickened or irregular vaginal mucosa/wall within the initial tumor extent (Fig. 4, Table 1). On imaging, T2-weighted MRI imaging abnormalities of thickened or deformed vaginal walls have a more hypointense fibrotic appearance and should be included.

In cases where tumors infiltrated the paravaginal or parametrial space at the time of diagnosis, but show regression during external beam radiation, these areas may appear as “gray zones” with intermediate T2 signal and should also be included in the CTV- T_{HR} target volume.

Intermediate-risk clinical target tumor volume (CTV- T_{IR})

The CTV- T_{IR} includes all potentially significant microscopic disease adjacent to the CTV- T_{HR} . This safety margin should be taken in the anatomic direction of microscopic spread. For the vagina, this is in the direction of the surrounding vaginal wall and the paravaginal space. CTV- T_{IR} should minimally include the area of the initial extent of disease at the time of diagnosis (GTV- T_{init}) and encompass a minimal safety margin of 0.5 cm added to the CTV- T_{HR} (Fig. 4, Table 1). When including the original extent of disease at diagnosis or applying the 0.5 cm safety margin in tissue, this expansion should be limited by the previously unaffected anatomic borders (eg, pubic bone, pelvic wall, pelvic floor musculature, bladder, urethra, mesorectal fascia, rectum, and anal sphincter). In cases where the GTV- T_{init} extends into surrounding organs and after EBRT there are no signs of macroscopic involvement of the organ wall, the previously affected organ wall should be included in the CTV- T_{IR} .

In high-risk histologies (eg, serous cancer), known extensive LVSI, or multifocality, it can be argued that the pattern of infiltration and spread and related margin required to

encompass tissue at risk of significant microscopic disease should be more than 0.5 cm. In these cases, one can consider adding a larger safety margin along the vaginal wall in the craniocaudal and circumferential directions. However, the expert panel could not find meaningful data to give exact evidence-based margin expansion recommendations for these specific cases at this time. It is important, however, to exclude the introitus and vulva whenever possible, as these regions can be more susceptible to necrosis.

Vagina outside of CTV- T_{HR}

The vagina is a target volume as well as an organ at risk (OAR). In the majority of cases, most of the vagina is included in the external beam target volume. However, at the time of brachytherapy, normal-appearing vagina outside of the brachytherapy target volume is regarded as an OAR. This has implications for dose reporting and provides opportunity for dose organ avoidance. Contouring the vagina outside of the CTV- T_{HR} gives a more consistent vaginal volume than contouring the vagina outside of CTV- T_{IR} (Fig. 4, Table 1). Thus, for delineation and reporting purposes, the normal-appearing vagina outside of the CTV- T_{HR} is regarded as most reproducible.

Special considerations

Complete response

In the rare case of a complete response to EBRT both on imaging and clinical examination, a CTV- T_{HR} cannot be delineated and only a CTV- T_{IR} can be contoured. This should include the initial extent of disease in the superior and inferior directions and the full thickness of the vaginal wall (Fig. 4). Generally, a lower dose might be prescribed in cases with a complete response. There is no consensus regarding whether the dose should be prescribed to the vaginal surface or to the full thickness of the vaginal wall. The purpose of defining the CTV- T_{IR} volume is not to specify where the dose should be prescribed but only to serve as a means of being able to have a standard target volume definition and related dose reporting so that outcomes can later be compared.

Discussion

There are multiple small institutional series demonstrating favorable local control and acceptable toxicities using IGABT in the management of vaginal recurrences of endometrial and cervical cancers. Although local control is typically in the 80% to 90% range, there is wide variation in disease-free and overall survival.¹¹⁻²² This reflects the heterogeneity of patients included in these studies, as well as the variation in dose specification, treatment volumes, and total dose, suggesting a need for more robust and consistent approaches. Improving outcomes for these patients presents

Table 1 Summary of consensus target definitions

Target	Definition	Comments
Residual gross tumor volume (GTV-T _{res})	Macroscopic gross tumor that remains at the time of brachytherapy as documented by clinical examination and/or imaging	*Has similar clinical and imaging characteristics as the initial GTV at diagnosis; on T2-weighted MRI this is the remaining mass with hyperintense to isointense signal intensity.
High-risk clinical target tumor volume (CTV-T _{HR})	Includes the GTV-T _{res} and areas on imaging and/or clinical examination that are concerning for harboring macroscopic pathologic disease. On clinical examination this should include any abnormal thickened or irregular fibrotic vaginal mucosa/wall within the initial tumor extent.	Has different clinical and imaging characteristics compared with GTV-T _{res} . On T2-weighted MRI pathologic abnormalities of thickened or deformed vaginal walls have a more hypointense fibrotic appearance and should also be included. In cases where tumors infiltrated the paravaginal or parametrial space at the time of diagnosis, after some regression during external beam radiation these areas may appear as “gray zones” and should also be included in the CTV-T _{HR} target volume.
Intermediate-risk clinical target tumor volume (CTV-T _{IR})	This should include at a minimum the initial extent of disease at the time of diagnosis (GTV-T _{init}), and should encompass a minimal safety margin of 0.5 cm added to the CTV-T _{HR} . In cases of high-risk histologies (eg, serous cancer) known extensive LVSI, or multifocality, one can consider adding a larger margin along the vaginal wall in the craniocaudal and circumferential directions. In the case of a complete response to external beam radiation both on imaging and clinical examination, only a CTV-T _{IR} is defined. This would include the original extent of disease in the superior and inferior direction and the full thickness of the vaginal wall to 0.5 cm tissue depth.	When including the original extent of disease at diagnosis or applying the minimal 0.5 cm safety margin in tissue, this expansion should be limited by the previously unaffected anatomic borders (eg, pubic bone, pelvic wall, pelvic floor musculature, bladder, urethra, mesorectal fascia, rectum, and anal sphincter).
Vagina	The CTV-T _{HR} should be excluded from the vaginal contour.	The normal-appearing vagina outside of the brachytherapy target volume is regarded as an organ at risk volume. For delineation and reporting purposes, the normal-appearing vagina outside of the CTV-T _{HR} is regarded most reproducible.
<p><i>Abbreviations:</i> CTV-T_{HR} = high-risk clinical target volume; CTV-T_{IR} = intermediate-risk clinical target volume; GTV = gross tumor volume; GTV-T_{init} = initial gross tumor volume; GTV-T_{res} = residual gross primary tumor volume; LVSI = lymph vascular space involvement; MRI = magnetic resonance imaging.</p> <p>* It is the responsibility of the radiation oncologist to define a composite volume that considers findings from clinical and imaging examinations, that by themselves may yield different volumes.</p>		

some challenges. Published image-guided brachytherapy studies include small numbers of patients and are mostly retrospective. To make progress, multi-institutional collaboration will be needed to pool cases for more meaningfully sized patient cohorts. The work from the EMBRACE group in locally advanced cervical cancer provides precedent for this type of model leading to practice-defining results.²⁷

In order for an EMBRACE-like effort to be successful for endometrial/cervical vaginal recurrences, there needs to be agreement on target definitions and reporting standards to facilitate data sharing and analysis. Some work has been done to establish consensus in this area. The ABS conducted a survey of variation in practices and target concepts for brachytherapy in recurrent endometrial cancers in the

vagina but no consensus on target definition was reached.²⁸ The CBG developed consensus concepts on vaginal tumor target definitions and conducted a contouring study to evaluate contouring consistency.²⁹ GEC-ESTRO published target concept recommendations for primary vaginal cancer but not for recurrent endometrial/cervical vaginal tumors.¹⁰ Finally, a review of published image-guided brachytherapy data for recurrent endometrial/cervical cancer demonstrates a wide range of brachytherapy target definitions (Table 2). To develop international consensus recommendations, members from GEC-ESTRO, ABS, and CBG agreed to collaborate to develop such consensus definitions.

At our initial meeting, there were significant variations in institutional practice resulting in variation in contours between participants. For example, when defining the CTV-T_{HR} in cases with well-lateralized disease, some participants included the entire circumference of the vagina while others only contoured the involved area as the high-risk target volume. For the CTV-T_{IR} there was even more variation, with some using a standard margin expansion on the CTV-T_{HR}, some including only the original extent of disease, and others contouring varying lengths of vagina outside of the CTV-T_{HR}. It was also apparent that there were uncertainties in interpreting the provided clinical case descriptions, clinical drawings, and MRI imaging. Trying to define the CTV-T_{HR} when incorporating the MRI findings with the clinical examination findings was often challenging. This was also true when trying to define the original extent of disease in cases where there was significant regression of the tumor after EBRT. Ultimately, the agreed-upon target definitions were very similar to those recently proposed by GEC-ESTRO for primary vaginal cancer, which are built on the concepts published in ICRU-89. There were, however, differences between the 2, including considerations around high-risk endometrial cancer histologies, multifocal disease, and LVSI.

Using the target volume consensus definitions, we saw improved agreement between participants after recontouring using the Kappa statistic. There were larger gains in agreement with the CTV-T_{HR} and CTV-T_{IR} compared with the GTV-T_{res}. There were similarly larger improvements in the CI for the CTV-T_{HR} and CTV-T_{IR} compared with the GTV-T_{res}. We used kappa and the CI because they have previously been used in other gynecologic contouring studies. In a study by Viswanathan et al of 3 definitive cervical cancer cases in which the HR CTV was contoured on MRI, the kappa values ranged from 0.64 to 0.67 and the CI from 0.38 to 0.48.³⁰ In another multi-institutional study of MRI-guided adaptive brachytherapy of cervical cancer, the CI for the HR CTV, IR CTV, and GTV were 0.76, 0.77, and 0.59, respectively.³¹ Finally, a recent NRG study of contours in the postoperative setting for gynecologic cancers reported kappa values for the common iliac, external iliac, para-aortic, internal iliac, and vaginal cuff regions as 0.64, 0.60, 0.58, 0.52, and 0.47, respectively.³² These results suggest that our results are in line with those of other gynecologic contouring studies. Also, the greater improvements in CTV-T_{HR} and CTV-T_{IR} relative to the GTV-T_{res} may be related to

challenges in defining disease once there's been significant tumor regression after EBRT and deformation from the vaginal applicator.

Although we made progress in agreeing on target volume definitions, there are a number of outstanding issues that were felt to be beyond the scope of this first consensus meeting. We recognize that not all practitioners are able to do MRI-based brachytherapy planning. There will be differences in defining the CTV-T_{HR} on MRI and CT given the differences in soft-tissue definition between the 2 modalities, with CT often overestimating the extent of residual disease. It was discussed that apart from contrast enhancement, CT could benefit from supplementary information through sonography and/or fiducial markers, in addition to the clinical findings. The proposed CTV-T_{IR} is a concept adapted from ICRU 89 for cervical cancer. It is meant to encompass areas thought to contain significant microscopic disease outside of the CTV-T_{HR} at the time of brachytherapy, and that require sufficient (intermediate) dose in addition to the elective dose for presumed microscopic disease at diagnosis. Approaches to create a CTV-T_{IR} include a variable margin around the CTV-T_{HR} (5-15 mm) and/or some combination of encompassing the original extent of disease with a margin. The expansion of the CTV-T_{IR} should be confined by previously unaffected anatomic borders. In the vagina, an expansion of 10 to 15 mm would be quite large and extend far into the bladder/rectum. The suggestion of a minimum 5 mm expansion is based on clinical experience and is consistent with the primary vaginal guidelines. However, the selection of 5 mm is not based on data showing that all significant microscopic disease is always within 5 mm of the HR CTV, and therefore may be enlarged in high-risk histologies with a presumed pattern of infiltration and/or expansion with a risk of significant microscopic tumor extending further. There is no way of knowing exactly what this margin should be, as it would require patients to get 45 Gy of EBRT and then to have radical surgery and review the final pathology. A 5-mm margin does, however, typically ensure that the entire thickness of the vagina will be included in the IR CTV volume. Most importantly, these consensus guidelines will offer standardization to allow future evaluation of this target concept in relation to tumor control and morbidity in sufficiently large data sets.

The IR CTV is not to be used as a prescription point but rather as a standardized target volume so that dose to this structure can be compared between institutions to determine how dose correlates with clinical outcomes. There was general agreement that rare patients with a complete response can be treated with lower doses than those with residual disease, but there are not enough published data to provide evidence-based recommendations on this. In the case of a complete response, there were also differences in opinions regarding whether the dose should be prescribed to the vaginal surface or to a depth (ie, fixed depth of 0.5 cm). This is a critical distinction because a dose, for example, of 7 Gy prescribed to 0.5 cm depth results in a vaginal surface dose of about 10.5 Gy. However, there is now

agreement to report the dose received to the CTV-T_{IR} in this situation. It was also beyond the scope of the meeting to make recommendations for dose specifications. Issues related to treatment planning were also not addressed. There were differences of opinion regarding plan optimization when using multichannel or interstitial brachytherapy. Some practitioners try to weigh the central channel heavily and limit the use of the peripheral channels/needles with the idea that this limits hot spots in the vaginal mucosa. The downside of this approach is that if a CTV-T_{HR} is well lateralized, then the whole vaginal circumference will essentially be treated. For this reason, others weigh the peripheral channels/needles more and weigh the central channel less in an effort to limit dose to the contralateral vaginal wall. It is not clear which is the preferred strategy. Regardless of the approach, the dose to the OARs should be kept as low as possible. Some of this is related to needing to improve our understanding of the dose/volume effect correlations for both the vaginal tumor and the acute and late-term OAR-related toxicities.

Finally, we went through multiple iterations of our target definitions to improve their clarity. With the second trial, there was a higher agreement (“substantial”) in the CTV-T_{HR} and CTV-T_{IR}, suggesting an improved shared understanding of target delineation. However, we recognize that this group of participants are all gynecologic specialists and have extensive experience in performing image-guided brachytherapy. We did not test whether these proposed definitions would be generalizable to a broader radiation oncology community. We anticipate, similar to other contouring guidelines, significant work will be needed to disseminate this information and to clarify areas of unanticipated confusion that may arise from reading/applying the proposed target definitions. Other limitations of our work include that not all participants were experts in MRI-based image-guided brachytherapy (some perform mostly CT-based brachytherapy), which could have influenced contouring agreement.

Conclusion

This international consensus provides recommendations for image-guided adaptive brachytherapy target definitions in vaginal recurrences of endometrial/cervical cancers. These target definitions will help facilitate collaboration between different centers to allow prospective validation and further evidence-based guidance that we anticipate will improve patient outcomes.

References

- Creutzberg CL, van Stiphout RGPM, Nout RA, et al. Nomograms for prediction of outcome with or without adjuvant radiation therapy for patients with endometrial cancer: A pooled analysis of PORTEC-1 and PORTEC-2 trials. *Int J Radiat Oncol Biol Phys* 2015;91:530-539.
- Peters III WA, Liu PY, Barrett II RJ, et al. Concurrent chemotherapy and pelvic radiation therapy compared with pelvic radiation therapy alone as adjuvant therapy after radical surgery in high-risk early-stage cancer of the cervix. *J Clin Oncol* 2000;18:1606-1613.
- Rotman M, Sedlis A, Piedmonte MR, et al. A phase III randomized trial of postoperative pelvic irradiation in Stage IB cervical carcinoma with poor prognostic features: Follow-up of a gynecologic oncology group study. *Int J Radiat Oncol Biol Phys* 2006;65:169-176.
- Creutzberg CL, Nout RA, Lybeert MLM, et al. Fifteen-year radiotherapy outcomes of the randomized PORTEC-1 trial for endometrial carcinoma. *Int J Radiat Oncol Biol Phys* 2011;81:e631-e638.
- Wortman BG, Creutzberg CL, Putter H, et al. Ten-year results of the PORTEC-2 trial for high-intermediate risk endometrial carcinoma: Improving patient selection for adjuvant therapy. *Br J Cancer* 2018;119:1067-1074.
- Bogani G, Ray-Coquard I, Concin N, et al. Uterine serous carcinoma. *Gynecol Oncol* 2021;162:226-234.
- León-Castillo A, de Boer SM, Powell ME, et al. Molecular classification of the PORTEC-3 trial for high-risk endometrial cancer: Impact on prognosis and benefit from adjuvant therapy. *J Clin Oncol* 2020;38:3388-3397.
- Sturdza A, Viswanathan AN, Erickson B, et al. American Brachytherapy Society working group report on the patterns of care and a literature review of reirradiation for gynecologic cancers. *Brachytherapy* 2020;19:127-138.
- Swamidias J, Mahantshetty U. ICRU Report 89: Prescribing, recording, and reporting brachytherapy for cancer of the cervix. *J Med Phys* 2017;42:48.
- Schmid MP, Fokdal L, Westerveld H, et al. Recommendations from gynaecological (GYN) GEC-ESTRO working group - ACROP: Target concept for image guided adaptive brachytherapy in primary vaginal cancer. *Radiother Oncol* 2020;145:36-44.
- Vargo JA, Kim H, Houser CJ, et al. Definitive salvage for vaginal recurrence of endometrial cancer: The impact of modern intensity-modulated-radiotherapy with image-based HDR brachytherapy and the interplay of the PORTEC 1 risk stratification. *Radiother Oncol* 2014;113:126-131.
- Huang K, D'Souza D, Patil N, et al. High-dose-rate interstitial brachytherapy for the treatment of high-volume locally recurrent endometrial carcinoma. *Brachytherapy* 2016;15:543-548.
- Chapman CH, Maghsoudi K, Littell RD, Chen L-M, Hsu I-C. Salvage high-dose-rate brachytherapy and external beam radiotherapy for isolated vaginal recurrences of endometrial cancer with no prior adjuvant therapy. *Brachytherapy* 2017;16:1152-1158.
- Sapienza LG, Ning MS, de la Pena R, et al. Outcomes and toxicity after salvage radiotherapy for vaginal relapse of endometrial cancer. *Int J Gynecol Cancer* 2020;30:1535-1541.
- Kamran SC, Manuel MM, Catalano P, et al. MR- versus CT-based high-dose-rate interstitial brachytherapy for vaginal recurrence of endometrial cancer. *Brachytherapy* 2017;16:1159-1168.
- Lee LJ, Damato AL, Viswanathan AN. Clinical outcomes following 3D image-guided brachytherapy for vaginal recurrence of endometrial cancer. *Gynecol Oncol* 2013;131:586-592.
- Alban G, Cheng T, Adelman J, et al. Definitive radiotherapy for vaginal recurrence of early-stage endometrial cancer: Survival outcomes and effect of mismatch repair status. *Int J Gynecol Cancer* 2021;31:1007-1013.
- Fokdal L, Ørtoft G, Hansen ES, et al. Toward four-dimensional image-guided adaptive brachytherapy in locally recurrent endometrial cancer. *Brachytherapy* 2014;13:554-561.
- Patel P, Deufel C, Haddock M, Petersen I. Preliminary results of modified interstitial MIAMI brachytherapy applicator for treatment of upper and apical vaginal tumors. *J Contemp Brachytherapy* 2020;12:562-571.
- Chopra S, Engineer R, Shah S, et al. MRI- and PET-guided interstitial brachytherapy for postsurgical vaginal recurrences of cervical cancer: Results of phase II study. *Int J Radiat Oncol Biol Phys* 2020;106:310-319.

21. Engineer R, Chopra S, Shukla R, et al. Computed tomography-based interstitial brachytherapy for recurrent cervical carcinoma in the vaginal apex. *Clin Oncol (R Coll Radiol)* 2022;34:e1-e6.
22. Murakami N, Kato T, Miyamoto Y, et al. Salvage high-dose-rate interstitial brachytherapy for pelvic recurrent cervical carcinoma after hysterectomy. *Anticancer Res* 2016;36:2413-2421.
23. Steiner A, Alban G, Cheng T, et al. Vaginal recurrence of endometrial cancer: MRI characteristics and correlation with patient outcome after salvage radiation therapy. *Abdom Radiol (NY)* 2020;45:1122-1131.
24. Landis JR, Koch GG. The measurement of observer agreement for categorical data. *Biometrics* 1977;33:159-174.
25. Allozi R, Li XA, White J, et al. Tools for consensus analysis of experts' contours for radiotherapy structure definitions. *Radiother Oncol* 2010;97:572-578.
26. Warfield SK, Zou KH, Wells WM. Simultaneous truth and performance level estimation (STAPLE): An algorithm for the validation of image segmentation. *IEEE Trans Med Imaging* 2004;23:903-921.
27. Potter R, Tanderup K, Schmid MR, et al. MRI-guided adaptive brachytherapy in locally advanced cervical cancer (EMBRACE-I): a multi-centre prospective cohort study. *Lancet Oncol* 2021;22:538-547.
28. Kamrava M, Beriwal S, Erickson B, et al. American Brachytherapy Society recurrent carcinoma of the endometrium task force patterns of care and review of the literature. *Brachytherapy* 2017;16:1129-1143.
29. Leung E, D'Souza D, Bachand F, et al. MRI-based interstitial brachytherapy for vaginal tumors: A multi-institutional study on practice patterns, contouring, and consensus definitions of target volumes. *Brachytherapy* 2019;18:598-605.
30. Viswanathan AN, Erickson B, Gaffney DK, et al. Comparison and consensus guidelines for delineation of clinical target volume for CT- and MR-based brachytherapy in locally advanced cervical cancer. *Int J Radiat Oncol Biol Phys* 2014;90:320-328.
31. Petric P, Dimopoulos J, Kirisits C, et al. Inter- and intraobserver variation in HR-CTV contouring: Intercomparison of transverse and para-transverse image orientation in 3D-MRI assisted cervix cancer brachytherapy. *Radiother Oncol* 2008;89:164-171.
32. Small Jr W, Bosch WR, Harkenrider MM, et al. NRG Oncology/RTOG consensus guidelines for delineation of clinical target volume for intensity modulated pelvic radiation therapy in postoperative treatment of endometrial and cervical cancer: An update. *Int J Radiat Oncol Biol Phys* 2021;109:413-424.